

Clinical and Radiographic Evaluation of *Allium sativum* Oil as a New Medicament for Vital Pulp Treatment of Primary Teeth

Shukry Gamal Mohammad¹, Syed Ahmed Raheel², Kusai Baroudi³

Contributors:

¹Assistant Professor, Department of Pediatric Dentistry, School of Dentistry, Al-Azhar University, Egypt; ²Lecturer, Department of Oral and Maxillofacial Sciences, Al-Farabi College of Dentistry & Nursing, Riyadh, Saudi Arabia; ³Assistant Professor, Department of Restorative Dental Sciences, Al-Farabi College of Dentistry & Nursing, Riyadh, Saudi Arabia.

Correspondence:

Dr. Baroudi K. Department of Restorative Dental Sciences, Al-Farabi Dental College, Riyadh, Kingdom of Saudi Arabia. Phone: +(0)966-12273151, Email: d_kusai@yahoo.co.uk

How to cite the article:

Mohammad SG, Raheel SA, Baroudi K. Clinical and radiographic evaluation of *Allium sativum* oil as a new medicament for vital pulp treatment of primary teeth. J Int Oral Health 2014;6(6):35-6.

Abstract:

Background: The objective of this study was to compare between the clinical and radiographic effects of *Allium sativum* oil and those of formocresol in vital pulpotomy in primary teeth.

Materials and Methods: A total of 20 children age ranged from 4 to 8 years were included in the study. In every one of those children, the primary molars indicated for pulpotomy. Pulpotomy procedure was performed, and the radicular pulp tissue of one molar capped with *A. sativum* oil in a cotton pellet, whereas the other molar capped with formocresol, the teeth evaluated clinically and radiographically before and after 6 months, using standard clinical and radiographical criteria. Statistically, these results revealed no significant difference between the radiographic findings of vital pulpotomy in primary molars with the two medicaments was found.

Results: *A. sativum* oil offers a good healing potential, leaving the remaining pulp tissue healthy and functioning. Vital pulpotomy with allium sativa oil was given raise 90% success rate while that with formocresol was 85%.

Conclusion: *A. sativum* oil is a biocompatible material that is compatible with vital human pulp tissue. It offers a good healing potential, leaving the remaining pulp tissue healthy and functioning.

Key Words: *Allium sativum*, formocresol, pulpotomy

Introduction

Preservation of the remaining vital portion of curiously exposed pulpal tissue in primary teeth, where the demand is to keep a functioning tooth in site, was one of the most frequent problems in pediatric dentistry.¹ To solve this problem pulpotomy therapy was introduced, developed and classified according to treatment objectives.² Pulpotomy involves amputation of the coronal portion of affected or infected dental pulp, treatment of the remaining vital radicular pulp tissue surface should preserve the vitality and function of all or part

of the remaining radicular portion of the pulp.³ Furthermore, it is an accepted procedure for treating both primary and permanent teeth with carious pulp exposures, several materials have been using for capping the radicular pulp after pulpotomy, these included formocresol, glutaraldehyde,⁴ ferric sulfate,⁵ the collagen material,⁶ and mineral trioxide aggregate.⁷

However, none of them had met the same degree of effectiveness and success rate as formocresol, possible hazards of formocresol (cytotoxicity, carcinogenicity, immunologic, biochemical, mutagenic, and teratogenic changes) in the host have been reported.⁸ Moreover, it produced enamel defects in the permanent successors.⁹ In this regard, the demand for natural medicament to replace formocresol as a pulp dressing material became imperative.

Most widely researched plants in the field of medicine is *Allium sativum*. The antibacterial activity of *A. sativum* is mediated by allicin through enzymatic activity of allinase (a cysteine sulfoxidelyase). A wide range of therapeutic effects reported for garlic is mainly from allicin and other thiosulfinates. The antibacterial effects of fresh garlic extract¹⁰ have been thoroughly researched via literature and have been found that the extract will inhibit growth of various Gram-positive and Gram-negative bacteria.¹¹ It is also reported that the garlic extract has inhibitory potential on isolated multi drug resistant strains of *Streptococcus mutans* from human caries teeth.¹²

Aim of the study

The aim of this study was to compare between the clinical and radiographic effects of *A. sativum* oil and those of formocresol in vital pulpotomy in primary teeth.

Materials and Methods

Twenty children age ranged from 4 to 8 years were selected from outpatient clinic of Pediatric Dentistry Department, Faculty of Dental Medicine, Al-Azhar University, Egypt.

Ethics of the study:

1. Care giver approval was taken.
2. Approval of Al-Azhar University, faculty of oral and dental medicine, Egypt (under number 249/2010).

A comprehensive history was obtained, and a thorough clinical examination was conducted on each of the selected children. A periapical radiograph of the intended tooth was achieved

before treatment. Moreover, asking the parents or caregivers about any medical problems that may contraindicate the use of any of the intended procedures. A diagnostic sheet had been made for each child including the personal information, clinical and radiographical evaluations. In every one of those children, a pair of primary molars indicated for pulpotomy was selected for treatment.

Inclusion criteria

1. Patient and parent cooperation
2. Absence of any systemic disease, which would contraindicate pulp therapy
3. Exposure of vital pulp after excavation of caries with no clinical evidence of the extensive pulp degeneration or any periapical pathologic condition
4. Absence of clinical signs or symptoms suggesting a non-vital tooth such as a suppurating sinus, soft tissue swelling, mobility or tenderness to percussion
5. Possibility for establishing a final restoration of the tooth.

Radiographic criteria

1. No pathological external or internal root resorption
2. No periapical radiolucency
3. No calcific pulp degeneration.

Technique

Molars to be treated were locally anaesthetized using mepecaine-L (a local anesthetic solution containing 20 mg Mepivacaine hydrochloride with 0.06 mg Levonordefrin hydrochloride). Patients were allowed to wait for 10-15 min before pulpotomy procedure was done, rubber dam or cotton rolls were used to isolate the designated molar. Cavity outline was established with a sterile #330 high-speed pear-shaped carbide bur with air/water spray. Caries was removed with a slow speed sterile round carbide burs. Access to a pulp chamber could be detected with a probe, or if the roof of the pulp chamber were sufficiently thin to see the pulpal tissue. When the pulpal exposure was confirmed, the roof of the pulp chamber was removed with a sterile, non-end cutting slow-speed bur. Removal of the coronal pulp tissue was achieved with a sterile low-speed carbide round bur and/or sharp, large, spoon excavator. Hemostasis was attained by placing small cotton pellet moistened in sterile saline with slight pressure then it was removed.

The pulp stumps of molars in the right side were dressed with a cotton pellet damped with *A. sativum* oil (Captin company (CAPpharm) registration No 952/94 Cairo, Egypt), and with formocresol (Petrópolis-RJ-Industria Brasileira, Dentsply, Latin America) for molars in the left side for 5 min. Then, pulp stumps of molars treated with *A. sativum* oil were dressed in zinc oxide - *A. sativum* oil paste, while those of teeth treated with formocresol were dressed with a thick paste prepared by mixing zinc oxide powder with

one drop of eugenol.^{13,14}

Then, a layer of intermediate restorative material zinc phosphate cement had been placed over the dressing materials. After that, molars were restored with suitable final restoration and then with stainless steel crowns. Then, molars were clinically and radiographically evaluated after 6 months, using standard clinical and radiographic criteria.

Clinical evaluation

1. History of pain related to the treated molars
2. Sensitivity to percussion
3. Teeth mobility
4. Signs of erythema, swelling, the presence of the fistulous tract in the surrounding gingival tissues and mucosa.

Radiographic evaluation

Periapical radiographs were taken for all treated molars (Ultra speed Kodak Periapical films, size 0 or 1 film). All radiographs taken during the follow-up period were screened for their diagnostic quality prior to being included in radiographic evaluation. Acceptable radiographs have non-distorted images of the treated molars and the osseous structures immediately adjacent to the roots. Radiographs that did not meet these criteria were excluded from the evaluation.

During radiographic evaluation, the following were determined:

1. Presence or absence (or reduce in size) of furcation or periapical radiolucency
2. Presence or absence of pathologic internal or external root resorption
3. Presence or absence of widening in the periodontal membrane.

Statistical analysis

Statistical analysis was performed between the clinical and radiographic effects of *A. sativum* oil and those of formocresol in vital pulpotomy in primary teeth using Chi-square, and the level of significance was taken at $\alpha = 0.05$.

Results

Clinical findings

The clinical findings of the primary molars treated with *A. sativum* oil after 6 months appeared as the following, from the 20 vital pulpotomies; only two cases had pain after 6 months. They were accompanied by increased mobility (Grade II) and recorded as treatment failure cases. For this reason, subtotal pulpectomy was performed for them. None of all cases developed a draining sinus.

The clinical outcomes of treated primary molars with formocresol after 6 months appeared as the following, from the 20 vital pulpotomies treated with formocresol, only four children had pain that recorded as treatment failure cases and treated by subtotal pulpectomy. None of all cases developed a draining sinus.

Comparisons between the clinical findings of vital pulpotomy in primary molars treated with allium sativa oil and those of formocresol are presented in Table 1 and Graph 1. Statistical analysis revealed no significant difference.

Radiographic findings

The radiographic outcomes of primary molars treated with *A. sativa* oil after 6 months showed, from the 20 vital pulpotomies; there were radiographic changes, only two molars showed evidence of widening in the periodontal membrane space. In addition, two cases exhibited periapical and furcation radiolucency after 6 months and considered as treatment failure cases. None of all treated molars exhibited root resorption. Moreover, the pericoronal sac associated with the underlying developing permanent teeth showed no noticeable changes (Figure 1).

The radiographic outcomes of primary molars treated with formocresol showed, from the 20 vital pulpotomies; there were radiographic changes, six primary molars showed evidence of widening in the periodontal membrane space.

In addition, four cases exhibited periapical, and two had furcation radiolucency after 6 months and considered as treatment failure cases. Furthermore, the teeth showed periapical and furcation radiolucency and considered as treatment failure cases, none of all treated molars exhibited root resorption. In addition, the pericoronal sac associated with the underlying developing permanent teeth showed no noticeable changes (Figure 2).

Comparisons between the radiographic findings of vital pulpotomy in primary molars treated with *A. sativa* oil and those of formocresol are presented in Table 2 and Graph 2. There was no noticeable difference compared to the aforementioned period.

Statistically, these results revealed no significant difference between the radiographic findings of vital pulpotomy in primary molars with the two medicaments was found.

Discussion

In this study, a comparison between the clinical and radiographic outcomes of *A. sativum* oil and formocresol as pulpotomy medicaments in primary molars was successfully obtained.

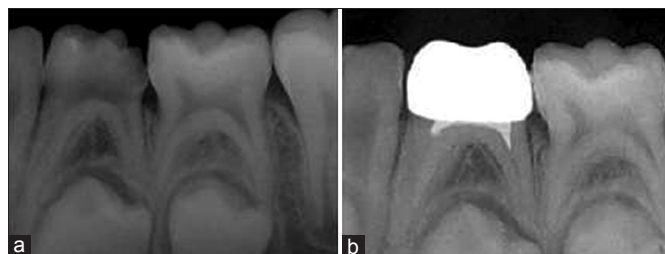


Figure 1: Radiographic features of the teeth treated with *Allium sativum* oil (vital pulpotomy). Mandibular first primary molar showed no changes at 6 months post-operative (b), compared to pre-operative radiograph (a).

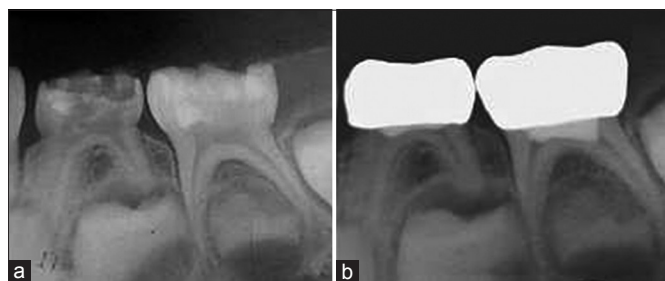


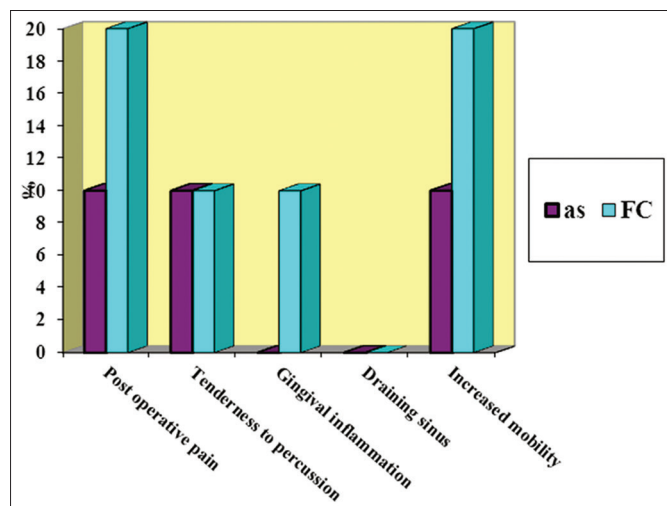
Figure 2: Radiographic features of the teeth treated with formocresol (vital pulpotomy). Mandibular first and second primary molars showed no changes at 6 months post-operative (b) compared to pre-operative radiograph (a).

Table 1: Comparison between the effects of <i>A. sativum</i> oil and those of formocresol on the clinical findings of the first group at 6 months.		
Clinical findings	<i>A. sativum</i> oil Count (%)	Formocresol Count (%)
Post-operative pain	2 (10)	4 (20)
Tenderness to percussion	2 (10)	2 (10)
Gingival inflammation	-	2 (10)
Draining sinus	-	-
Increased mobility	2 (10)	4 (20)

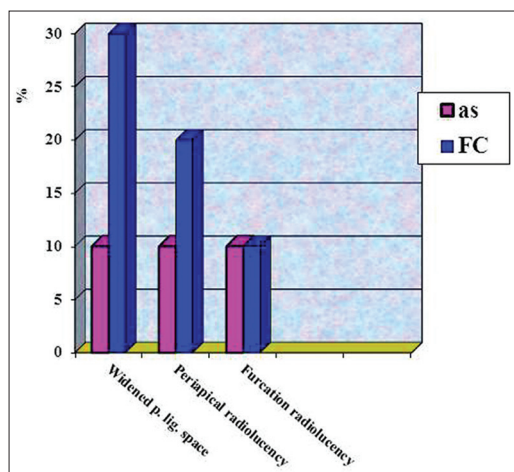
P<0.05

Table 2: Comparison between the effects of <i>A. sativum</i> oil and those of formocresol on the radiographic findings of the first group at 6 months.		
Radiographic findings	<i>A. sativum</i> oil Count (%)	Formocresol Count (%)
Widened periodontal ligament space	2 (10)	6 (30)
Periapical radiolucency	2 (10)	4 (20)
Furcation radiolucency	2 (10)	2 (10)

P<0.05



Graph 1: A histogram showing a comparison between the effects of *Allium sativum* oil (AS) and those of formocresol (FC) on the clinical findings at 6 months post-operative.



Graph 2: A histogram showing comparison between the effects of *Allium sativum* oil and those of formocresol on the radiographic findings at 6 months post-operative.

Since formocresol is still considered the standard in primary teeth pulp therapy, hence it was used in the present study as a control. Due to its hazardous effects it produced enamel defects in the permanent successors.¹⁵ A systemic uptake of formocresol has been found from pulpotomized teeth, and tissue changes have occurred in various internal organs, particularly in kidney and liver, the quantity of circulating formocresol was found to increase with the number of teeth treated.¹⁶ It is known to have toxic, mutagenic and carcinogenic potential (Hill *et al.*, 1991).¹⁷ In this regard, a demand for medicament to replace formocresol as a pulp dressing material became imperative.

Despite the penetration of the modern medicine, traditional medicine continues to be a viable health alternative for the large underprivileged sections of the world.¹⁸ Hence, increase utilization of indigenous plant medicines in developing countries became a World Health Organization policy in the 1970's.¹⁹ Medicinal plants constitute a promising source of several drugs, among the promising medicinal plants, *allium sativa*, which considered being an amazing herb with a rich historical and religious background.¹¹ In spite of the fact that *allium sativa* oil was used for the first time in treatment of vital primary molars, the results were remarkable and promising, as none of the succeeded cases showed any signs or symptoms of morbidity during the whole follow-up period. Moreover, no obvious radiographic changes were noticed during the recall visits.

In the present study, the results revealed that the success rate of *A. sativum* oil was 90%, while the success rate of formocresol was 85%. In general, these results confirmed the success rate of formocresol in treatment of vital pulps of primary molars and it is in agreement with other studies,²⁰ however, the success rate of formocresol in the present study was lower than that suggested by others. In their study, 100% clinical success rate with formocresol was reported.¹³

The promising clinical outcome of vital pulpotomy performed with *allium sativa* oil may be explained on the bases that the oil was found to possess a potent analgesic and anti-inflammatory properties and it is used in the folk medicine for treatment of toothache without any side effects, The analgesic effect might be due to ajoene and diallyl sulfide, which inhibit prostaglandin, the anti-inflammatory effect of *allium sativa* was reported by several investigators.²¹ It inhibits prostaglandins through the suppression of cyclooxygenase enzyme in the inflamed area, and inflammatory cytokines.²² It also inhibits prostaglandins through suppression of 5-lipoxygenase enzyme. In addition, allicin and ajoene appear to inhibit nitric oxide synthesis in macrophages.²³ Nitric oxide (a pro-inflammatory mediator) is produced by macrophages.²⁴

In this study, there was a high prevalence of furcation pathosis determined by radiographic examination. This finding is in agreement with another study.²⁵

In the present study, radiographic investigation revealed an improvement, at the end of the follow-up period, with both *allium sativa* oil and formocresol treated teeth. This finding agrees with other investigators. The clinical and radiographic results revealed success at the aforementioned interval, if the recall periods were continued longer, complete resolution of these changes could be occurred. Statistical analysis revealed no significant difference between the effects of both medicaments on the clinical and radiographic outcomes.

Conclusions

A. sativum oil offers a good healing potential, leaving the remaining pulp tissue healthy and functioning. Statistically, there was no significant difference in the clinical and radiographic success rates of vital pulpotomies in primary molars treated with either *A. sativum* oil or formocresol.

References

1. Primosch RE, Glomb TA, Jerrell RG. Primary tooth pulp therapy as taught in predoctoral pediatric dental programs in the United States. *Pediatr Dent* 1997;19:118-22.
2. Hicks MJ, Barr ES, Flaitz CM. Formocresol pulpotomies in primary molars: A radiographic study in a pediatric dentistry practice. *J Pedod* 1986;10(4):331-9.
3. Estrela C, Holland R, Bernabé PF, de Souza V, Estrela CR. Antimicrobial potential of medicaments used in healing process in dogs' teeth with apical periodontitis. *Braz Dent J* 2004;15(3):181-5.
4. Loos PJ, Han SS. An enzyme histochemical study of the effect of various concentrations of formocresol on connective tissues. *Oral Surg Oral Med Oral Pathol* 1971;31(4):571-85.
5. Fuks AB, Eidelman E, Cleaton-Jones P, Michaeli Y. Pulp response to ferric sulfate, diluted formocresol and IRM in pulpotomized primary baboon teeth. *ASDC J Dent Child* 1997;64(4):254-9.

6. Garcia-Godoy F. A 42 month clinical evaluation of glutaraldehyde pulpotomies in primary teeth. *J Pedod* 1986;10(2):148-55.
7. Schwartz RS, Mauger M, Clement DJ, Walker WA 3rd. Mineral trioxide aggregate: A new material for endodontics. *J Am Dent Assoc* 1999;130(7):967-75.
8. Myers DR, Shoaf HK, Dirksen TR, Pashley DH, Whitford GM, Reynolds KE. Distribution of ¹⁴C-formaldehyde after pulpotomy with formocresol. *J Am Dent Assoc* 1978;96(5):805-13.
9. Lewis BB, Chestner SB. Formaldehyde in dentistry: A review of mutagenic and carcinogenic potential. *J Am Dent Assoc* 1981;103(3):429-34.
10. Tsao SM, Yin MC. *In-vitro* antimicrobial activity of four diallyl sulphides occurring naturally in garlic and Chinese leek oils. *J Med Microbiol* 2001;50(7):646-9.
11. Martin KW, Ernst E. Herbal medicines for treatment of bacterial infections: A review of controlled clinical trials. *J Antimicrob Chemother* 2003;51(2):241-6.
12. Fani MM, Kohanteb J, Dayaghi M. Inhibitory activity of garlic (*Allium sativum*) extract on multidrug-resistant *Streptococcus mutans*. *J Indian Soc Pedod Prev Dent* 2007;25(4):164-8.
13. Rölling I, Thylstrup A. A 3-year clinical follow-up study of pulpotomized primary molars treated with the formocresol technique. *Scand J Dent Res* 1975;83(2):47-53.
14. van Amerongen WE, Mulder GR, Vingerling PA. Consequences of endodontic treatment in primary teeth. Part I: A clinical and radiographic study of the influence of formocresol pulpotomy on the life-span of primary molars. *ASDC J Dent Child* 1986;53(5):364-70.
15. Meyer FW, Sayegh FS. Wound healing following curettage of bifurcation abscesses of human primary molars. *Oral Surg Oral Med Oral Pathol* 1979;47(3):267-74.
16. Ranly DM, Horn D. Assessment of the systemic distribution and toxicity of formaldehyde following pulpotomy treatment. *ASDC J Dent Child* 1987;54:40-46.
17. Hill SD, Berry CW, Seale NS, Kaga M. Comparison of antimicrobial and cytotoxic effects of glutaraldehyde and formocresol. *Oral Surg Oral Med Oral Pathol* 1991;71(1):89-95.
18. Tahraoui A, El-Hilaly J, Israili ZH, Lyoussi B. Ethnopharmacological survey of plants used in the traditional treatment of hypertension and diabetes in south-eastern Morocco (Errachidia province). *J Ethnopharmacol* 2007;110(1):105-17.
19. Haq A, Lobo PI, Al-Tufail M, Rama NR, Al-Sedairy ST. Immunomodulatory effect of *Nigella sativa* proteins fractionated by ion exchange chromatography. *Int J Immunopharmacol* 1999;21(4):283-95.
20. Droter JA. Pulp therapy in primary teeth. *J Dent Child* 1967;34(6):507-10.
21. Hajhashemi V, Ghannadi A, Jafarabadi H. Black cumin seed essential oil, as a potent analgesic and anti-inflammatory drug. *Phytother Res* 2004;18(3):195-9.
22. Wagner H, Wierer M, Fessler B. Effects of garlic constituents on arachidonate metabolism. *Planta Med* 1987;53(3):305-6.
23. Numagami Y, Sato S, Ohnishi ST. Attenuation of rat ischemic brain damage by aged garlic extracts: A possible protecting mechanism as antioxidants. *Neurochem Int* 1996;29(2):135-43.
24. El-Mahmoudy A, Matsuyama H, Borgan MA, Shimizu Y, El-Sayed MG, Minamoto N, et al. Thymoquinone suppresses expression of inducible nitric oxide synthase in rat macrophages. *Int Immunopharmacol* 2002;2(11):1603-11.
25. Binns WH Jr, Escobar A. Defects in permanent teeth following pulp exposure of primary teeth. *J Dent Child* 1967;34(1):4-14.