

Long Term Stability and Relapse Following Mandibular Advancement and Mandibular Setback Surgeries: A Cephalometric Study

S Vinay Darshan¹, Yusuf Ahammed Ronad², M S V Kishore³, K Sadashiva Shetty⁴, M Rajesh⁵, S D Suman⁶

Contributors:

¹Reader, Department of Orthodontics, College of Dental Science, Bhavnagar, Gujarat, India; ²Reader, Department of Orthodontics, School of Dental Sciences, Karad, Satara, Maharashtra, India; ³Professor, Department of Orthodontics, SVS Institute of Dental Science, Mahbubnagar, Telangana, India; ⁴Professor and Head, Department of Orthodontics, Bapuji Dental College, Davangere, Karnataka, India; ⁵Reader, Department of Orthodontics, M R Ambedkar Dental College, Bengaluru, Karnataka, India; ⁶Tutor, Department of Prosthodontics, College of Dental Science, Bhavnagar, Gujarat, India.

Correspondence:

Dr. Darshan SV. Department of Orthodontics, College of Dental Science, Bhavnagar, Gujarat, India. Email: vinaydarshan@gmail.com

How to cite the article:

Darshan SV, Ronad YA, Kishore MS, Shetty KS, Rajesh M, Suman SD. Long term stability and relapse following mandibular advancement and mandibular setback surgeries: A cephalometric study. J Int Oral Health 2014;6(5):42-6.

Abstract:

Background: The aim was to evaluate the long-term hard and soft tissue changes following mandibular advancement and setback surgeries.

Materials and Methods: A total of 16 subjects each were selected who underwent bilateral sagittal split osteotomy mandibular advancement and mandibular setback groups. Pre-surgical (T1), immediate post-surgical (T2) and long-term post-surgical (T3) cephalograms were compared for hard and soft tissue changes. After cephalometric measurements, the quantity of changes between T1-T2 and T1-T3 were determined for each patient. The mean difference between T1-T2 and T1-T3 was compared with assess the long-term changes and stability.

Results: In mandibular advancement the mean difference between immediate post-surgical and long term post-surgical is 7%, which accounts for a relapse of 7%. In mandibular setback, the mean difference between immediate post-surgical and long-term post-surgical is 29%, which accounts for a relapse of 29%.

Conclusion: Mandibular advancement remained stable over the long period when compared to mandibular setback.

Key Words: Stability, surgical mandibular advancement, surgical mandibular setback

Introduction

The present generation usually recognizes irregular teeth or obvious jaw deformities and seeks treatment from an orthodontist, for improving teeth alignment, function, and facial esthetics. Among these, Once growth is ceased some

patients neither growth modification nor the camouflage would be a possible solution; surgery is the only way to correct, a jaw discrepancy.^{1,2} Development of the bilateral sagittal split osteotomy (BSSO) by "Trauner and Obwegesser" in 1957, revolutionized the correction of mandibular defects. During the last two decades, many studies were undertaken to evaluate the short term changes, but in recent years the stability of orthognathic surgical procedures has been questioned on a long-term evaluation. Therefore, this study is intended to evaluate the stability and relapse of soft and hard tissues following mandibular advancement and mandibular setback surgeries.^{3,4}

Materials and Methods

Data collection

Pre-surgical (T1), immediate post-surgical (T2) and long-term post-surgical (T3) cephalograms of 16 adult patients out of which 8 were mandibular advancement, and 8 were mandibular setback, treated with BSSO procedure was taken. The age group of these patients ranged from 17 years to 26 years. Long term post-surgical cephalograms were taken, minimum of 12 months after surgery.

Analysis of lateral cephalograms

Standardized pre-surgical, immediate post-surgical and long term post-surgical profile cephalograms were taken in occlusion under standardized conditions with a cephalostat. Various angular and linear parameters of different cephalometric analysis such as Burstone's hard and soft tissue, Steiner's, McNamara, Holdaway and Rakosi Jarabak analysis were employed in this study (Tables 1 and 2).⁵⁻¹⁰

Procedure

All radiographs were hand traced on acetate paper and measured by the same person. Linear and angular parameters which are mentioned in Tables 1 and 2 were used. After cephalometric measurements were made the quantity of changes between T1-T2 and T1-T3 were determined for each patient. The mean difference between T1-T2 and T1-T3 was compared with assess the long-term changes and stability (Figures 1 and 2).

Results

Results are expressed as mean and percentage changes. Long term post-surgical changes compared to pre-surgical changes, and immediate post-surgical changes were compared by

Paired-t test for mandibular advancement and mandibular setback. Further, the amount of relapse in both types of surgeries was compared and analyzed using unpaired t-test. P value of 0.05 or less was considered for statistical significance. The results are shown as follows in (Graphs 1-4 and Tables 3-7).

Discussion

Patients undergo orthognathic surgical procedures to improve esthetics and functional problems. The interdigitation of the dentition in all three planes determines the positioning of the

jaws at surgery and helps in attaining stable results. According to the hierarchy of stability, the most stable surgical procedure was superior repositioning of the maxilla, closely followed by mandibular advancement in patients with decreased or normal anterior facial height. Forward movement of the maxilla was reasonably stable, but mandibular setback often was unstable and transverse widening of the maxilla was the least stable procedure.

In mandibular advancement as expected, the ANB angle showed a significant decrease immediately following surgery

Table 1: Hard tissue evaluation.	
Angular parameters	
N-A-Pog (Angle of convexity)	
MP-HP angle	
ANB angle	
N-Pog/FH	
Ar-Go-Gn	
Linear parameters	
N-B	
N-Pog	
ANS-Gn	
Go-Pog	

Table 2: Soft tissue evaluation.	
Angular parameters	
G-Sn-Pog' (Angle of convexity)	
Sn-Gn'-C (lower face throat angle)	
Cm-Sn-Ls (Nasolabial angle)	
N'-Pog'/FH	
N'-Pog'/Pog'-Ls	
Linear parameters	
G-Sn/Sn-Me' (anterior facial height proportionality)	
Sn-Gn'/C-Gn' (lower vertical height-depth ratio)	
Li to (Sn-Pog') (lower lip protrusion)	
Si to (Li-Pog') (mentolabial sulcus)	
E-line (Esthetic Plane)	
Pog-Pog', Gn-Gn', Me-Me'	

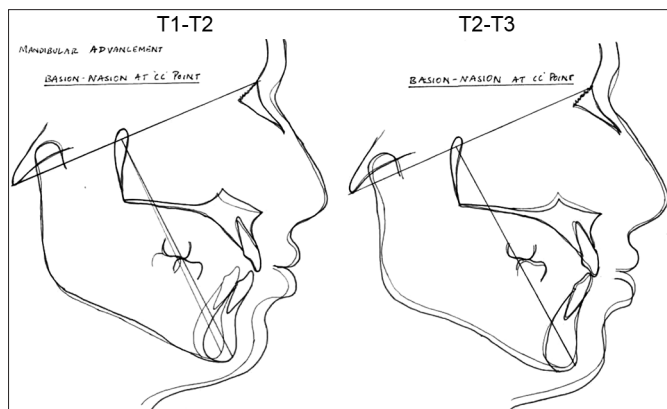
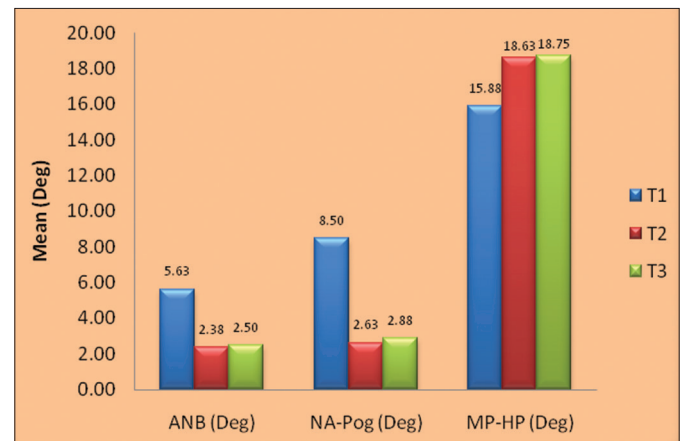


Figure 1: Superimposition – mandibular advancement (T1: Pre-treatment, T2: Post-surgical, T3: Long term post-surgical).



Graph 1: Hard tissue angular (mandibular advancement).

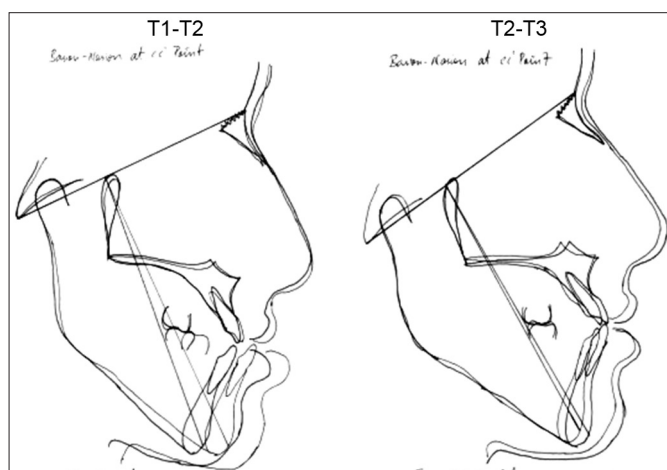
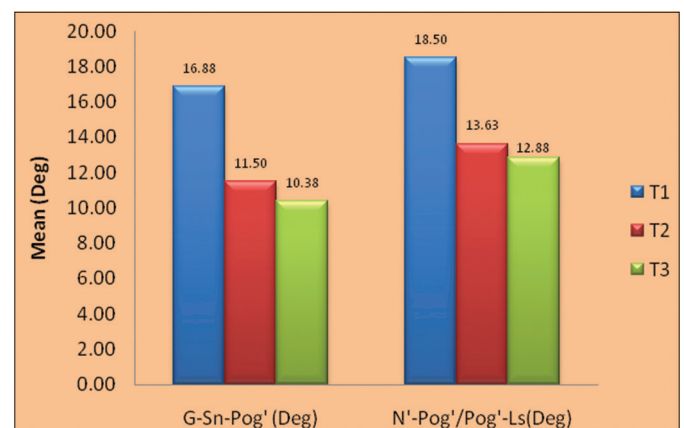


Figure 2: Superimposition – mandibular setback (T1: Pre-treatment, T2: Post-surgical, T3: Long term post-surgical).



Graph 2: Soft tissue angular (mandibular advancement).

Table 3: Hard tissue angular.

Parameters	T1	T2	T3	T1-T2	P* value, significant	T1-T3	P* value, significant	T2-T3	% change	P* value, significant
ANB (°)	5.63	2.38	2.50	3.25	P<0.001 HS	3.13	P<0.001 HS	-0.13	-5	P>0.05 NS
NA-Pog (°)	8.50	2.63	2.88	5.88	P<0.001 HS	5.63	P<0.001 HS	-0.25	-10	P>0.05 NS
MP-HP (°)	15.88	18.63	18.75	-2.75	P>0.05 NS	-2.88	P>0.05 NS	-0.13	-1	P>0.05 NS
FH-N-Pog (°)	86.38	88.13	88.25	-1.75	P<0.05 S	-1.88	P<0.05 S	-0.13	0	P>0.05 NS
Ar-Go-Gn (°)	112.13	116.50	117.63	-4.38	P<0.001 HS	-5.50	P<0.05 S	-1.13	-1	P>0.05 NS

S: Significant, NS: Non-significant

Table 4: Hard tissue linear.

Parameters	T1	T2	T3	T1-T2	P* value, significant	T1-T3	P* value, significant	T2-T3	% change	P* value, significant
N-B (mm)	10.50	4.00	4.75	6.50	P<0.05 S	5.75	P<0.05 S	0.75	7	P>0.05 NS
N-Pog (mm)	8.50	2.50	2.50	6.00	P<0.05 S	6.00	P<0.05 S	0.00	0	P>0.05 NS
ANS-Gn (mm)	58.50	64.88	62.38	-6.38	P<0.05 S	-3.88	P<0.001 HS	2.50	4	P>0.05 NS
Go-Pog (mm)	79.00	84.25	83.88	-5.25	P<0.001 HS	-4.88	P<0.001 HS	0.38	0	P>0.05 NS

S: Significant, NS: Non-significant, HS: Highly significant

Table 5: Soft tissue angular.

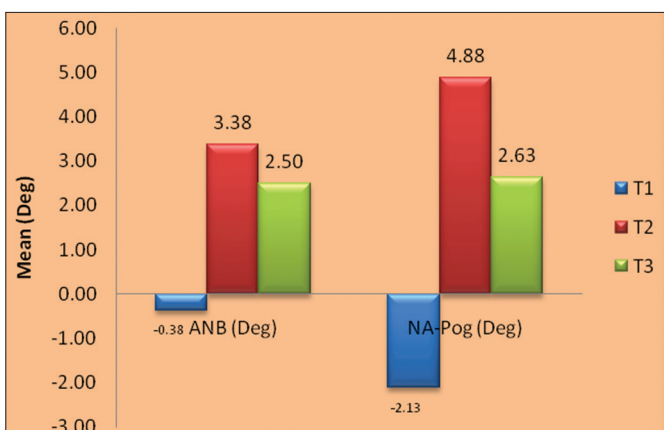
Parameters	T1	T2	T3	T1-T2	P* value, significant	T1-T3	P* value, significant	T2-T3	% change	P* value, significant
G-Sn-Pog' (°)	16.88	11.50	10.38	5.38	P<0.001 HS	6.50	P<0.001 HS	1.13	10	P>0.05 NS
Sn-Gn'-C (°)	123.75	116.63	116.88	7.13	P<0.05 S	6.88	P<0.05 S	-0.25	0	P>0.05 NS
Cm-Sn-Ls (°)	102.88	106.38	101.38	-3.50	P>0.05 NS	1.50	P>0.05 NS	5.00	5	P>0.05 NS
N'-Pog'/FH (°)	88.50	90.13	90.63	-1.63	P<0.05 S	-2.13	P<0.05 S	-0.50	-1	P>0.05 NS
N'-Pog'/Pog'-Ls (°)	18.50	13.63	12.88	4.88	P<0.001 HS	5.63	P<0.05 S	0.75	6	P>0.05 NS

S: Significant, NS: Non-significant, HS: Highly significant

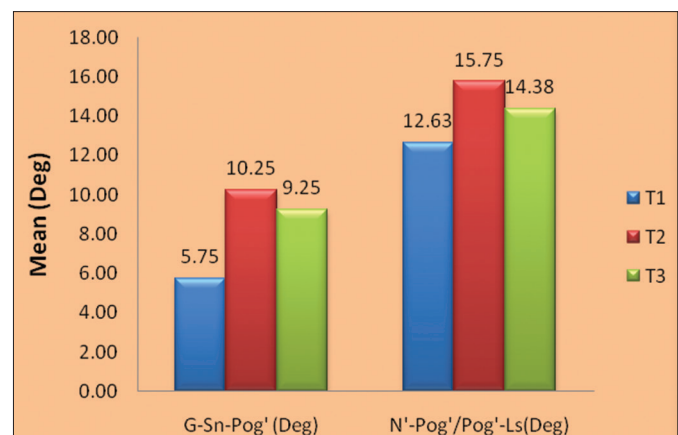
Table 6: Soft tissue linear.

Parameters	T1	T2	T3	T1-T2	P* value, significant	T1-T3	P* value, significant	T2-T3	% change	P* value, significant
G-Pog' (mm)	-6.25	1.00	-0.13	-7.25	P<0.001 HS	-6.13	P<0.001 HS	1.13	113	P<0.05 S
G-Sn/Sn-Me' (mm)	1.25	0.99	1.02	0.26	P>0.05 NS	0.23	P>0.05 NS	-0.03	-3	P>0.05 NS
Sn-Gn'/C-Gn' (mm)	1.08	0.97	1.02	0.11	P>0.05 NS	0.06	P>0.05 NS	-0.05	-5	P>0.05 NS
Li to Sn-Pog' (mm)	2.13	2.88	2.75	-0.75	P>0.05 NS	-0.63	P>0.05 NS	0.13	4	P>0.05 NS
Si to Li-Pog' (mm)	2.13	1.00	1.13	1.13	P<0.05 S	1.00	P<0.05 S	-0.13	-13	P<0.05 S
E line to UL (mm)	-2.75	-3.88	-4.38	1.13	P<0.05 S	1.63	P>0.05 NS	0.50	-13	P<0.05 S
E line to LL (mm)	-2.88	-0.75	-2.13	-2.13	P>0.05 NS	-0.75	P>0.05 NS	1.38	-183	P>0.05 NS
Pog-Pog' (mm)	11.75	11.38	11.50	0.38	P>0.05 NS	0.25	P>0.05 NS	-0.13	-1	P>0.05 NS
Gn-Gn' (mm)	10.38	10.25	10.25	0.13	P>0.05 NS	0.13	P>0.05 NS	0.00	0	P>0.05 NS
Me-Me' (mm)	9.38	9.00	9.00	0.38	P>0.05 NS	0.38	P>0.05 NS	0.00	0	P>0.05 NS

S: Significant, NS: Non-significant, HS: Highly significant



Graph 3: Hard tissue angular (mandibular setback).



Graph 4: Soft tissue angular (mandibular setback).

Table 7: Comparison between mandibular advancement and mandibular setback.

Linear parameter (NB) mm	T1	T2	T3	T1-T2	% change	T1-T3	% change	T2-T3	% change	P* value, significant
Mandibular advancement	10.50	4.00	4.75	6.50	62	5.75	55	-0.75	7	P>0.05 NS
Mandibular setback	3.75	3.50	3.38	1.48	39	0.38	10	0.13	29	P<0.05 S

S: Significant, NS: Non-significant

and was found to be stable in the long term.^{9,10} The mean sagittal relapse at hard tissue Pogonion was 10% of the sagittal correction which was not significant. Vertically, in the short term, the lower anterior facial height increased as evident by an increase in linear measurement given by the parameter ANS-Gn. This was found to be stable as there was no significant change in the variable in the long-term.^{7,8} In mandibular setback, there was increase in the ANB angle following surgery, but in a long run it showed significant relapse, which is similar to a study reported by Mobarak *et al.* This could be because of several factors that have been cited as responsible for relapse following mandibular setback surgery, including altered activity and failure of masticatory muscles to adapt to the repositioned segment, altered condylar position secondary to rotation or distraction of the proximal segment during fixation, positional change of the tongue with reduced space after setback. The mean sagittal relapse at hard tissue Pogonion was 25% of the sagittal correction. Lower anterior facial height remained the same from pre-surgical to immediate post-surgical and long term post-surgical, indicating a pure setback of the mandible without any rotation. This was similar to the findings obtained by Robinson *et al.*³

Within the mandible: In mandibular advancement in the short term the gonial angle and mandibular plane showed mild opening, which gradually decreased though the amount of change is not clinically significant over the long-term evaluation.¹¹⁻¹⁴ In mandibular setback gonial angle and mandible plane remained the same from pre-surgical to immediate post-surgical and, long term post-surgical, indicating a pure setback of the mandible without any rotation. This observed mean stability is most likely due to careful surgical technique in which the muscles were stretched minimally. The bony interface was well-prepared for a close union, and control of the proximal segments was maintained in order to minimize any distal or clockwise rotation as suggested by Sorokolit and Nanda. Although the observed mean vertical changes were not statistically significant, but individual data indicated there was considerable variability of post-surgical vertical changes.^{15,16} Change of 2.0 mm has been accepted as a cutoff value at which post-operative changes begin to be of clinical significance as stated by Proffit.¹⁷⁻²⁰ Several studies have drawn particular attention to the lack of control of the proximal segment, which has 2 aspects: Change in the condyle/fossa relationship and rotation of the segment as a whole. Schatz and Tsimas proposed that the surgeon may

seat the condyles too far posteriorly and, since rigid fixation maintains the proximal segment in an upright position, the post-surgical changes are expressed horizontally.

Soft tissue changes

In mandibular advancement, the present study showed that in the short term, there were significant changes in the angle of facial convexity and lower face throat angle. These changes were found to be stable in the long term. There was no change in the nasiolabial angle in the short term and long term, and demonstrated a reduction in lower lip thickness, as well as lengthening and straightening with an accompanying decrease of the mentolabial fold. In relation to chin the area, the soft tissue pogonion, menton and gnathion followed their hard tissue counter parts in the ratio of 1:1 in short and long term, similar to the findings of Hunt and Rudge (1984).¹¹

In mandibular setback, Significant variations were found in the angular parameters of N'-Pog'/Pog'-Ls and throat angle. Although, the anterior face height was not altered, upper lip flattened similarly to reports by Kajikawa.

The results of the current study indicate a definite improvement in the facial profile and lip competence from pre-surgical to immediate post-surgical and there are no significant changes from post-surgical to long-term evaluation, which is supported by GJORUP and ATHANASIOU (1991)¹⁷ and Suckiel and Kohn (1978).⁶

In general, skeletal class III patients who were treated with surgery experienced minimum change in the soft tissues with a follow-up period of two to three years. However as age advances there is a tendency to have an increase in soft tissue thickness at chin, thinning of the lips and downward sag of the soft tissue profile, which has to be evaluated critically.¹⁸⁻²⁰

Conclusion

In mandibular advancement the mean difference between pre-surgical and immediate post-surgical is 62% and between pre-surgical and long-term post-surgical is 55%, between immediate post-surgical and long-term post-surgical is 7%, which accounts for a relapse of 7%. The reasons for relapse can be linked to condylar position in the glenoid fossa during internal fixation, lack of proximal segment control at the time of surgery, Paramandibular connective tissue tension, Advancements more than 7 mm, is associated with the increased tendency of relapse. Most of these changes were found to be stable in the long-term.

In mandibular setback, the mean difference between pre-surgical and immediate post-surgical is 39% and between pre-surgical and long-term post-surgical is 10%, between immediate post-surgical and long-term post-surgical is 29%, which accounts for a relapse of 29%. The reasons for relapse can be linked to Post-surgical pull of the pterygomasseteric sling. In the case of mandibular excess, the lever arm of the mandible is shortened with retrusion, increasing mechanical advantage while chewing or biting. On the other hand, muscle fiber length of the pterygomasseteric sling is lengthened or stretched with retrusion. This fact probably accounts for the greater relapse tendency of failure of the other masticatory muscles to adapt to the new environment, positional change of the tongue with reduced space after setback, magnitude of setback.

References

1. Proffit WR, Fields HW Jr. Contemporary Orthodontics, 4th ed. St. Louis: Mosby; 2007.
2. Graber TM, Vanarsdall RL Jr. Current Principles and Techniques, 3rd ed. St Louis: Mosby; 2000.
3. Robinson SW, Speidel TM, Isaacson RJ, Worms FW. Soft tissue profile change produced by reduction of mandibular prognathism. *Angle Orthod* 1972;42(3):227-35.
4. Hershey HG, Smith LH. Soft-tissue profile change associated with surgical correction of the prognathic mandible. *Am J Orthod* 1974;65(5):483-502.
5. Burstone CJ, James RB, Legan H, Murphy GA, Norton LA. Cephalometrics for orthognathic surgery. *J Oral Surg* 1978;36(4):269-77.
6. Suckiel JM, Kohn MW. Soft-tissue changes related to the surgical management of mandibular prognathism. *Am J Orthod* 1978;73(6):676-80.
7. Legan HL, Burstone CJ. Soft tissue cephalometric analysis for orthognathic surgery. *J Oral Surg* 1980; 38(10):744-51.
8. Lake SL, McNeill RW, Little RM, West RA. Surgical mandibular advancement: A cephalometric analysis of treatment response. *Am J Orthod* 1981;80(4):376-94.
9. Holdaway RA. A soft-tissue cephalometric analysis and its use in orthodontic treatment planning. Part I. *Am J Orthod* 1983;84(1):1-28.
10. Ellis E 3rd, Carlson DS. Stability two years after mandibular advancement with and without suprahyoid myotomy: An experimental study. *J Oral Maxillofac Surg* 1983;41(7):426-37.
11. Hunt NP, Rudge SJ. Facial profile and orthognathic surgery. *Br J Orthod* 1984;11(3):126-36.
12. Van Sickels JE, Flanary CM. Stability associated with mandibular advancement treated by rigid osseous fixation. *J Oral Maxillofac Surg* 1985;43(5):338-41.
13. Ellis E 3rd, Gallo WJ. Relapse following mandibular advancement with dental plus skeletal maxillomandibular fixation. *J Oral Maxillofac Surg* 1986;44(7):509-15.
14. Franco JE, Van Sickels JE, Thrash WJ. Factors contributing to relapse in rigidly fixed mandibular setbacks. *J Oral Maxillofac Surg* 1989;47(5):451-6.
15. Lew KK, Loh FC, Yeo JF, Loh HS. Evaluation of soft tissue profile following intraoral ramus osteotomy in Chinese adults with mandibular prognathism. *Int J Adult Orthodon Orthognath Surg* 1990;5(3):189-97.
16. Sorokolit CA, Nanda RS. Assessment of the stability of mandibular setback procedures with rigid fixation. *J Oral Maxillofac Surg* 1990;48(8):817-22.
17. Gjørup H, Athanasiou AE. Soft-tissue and dentoskeletal profile changes associated with mandibular setback osteotomy. *Am J Orthod Dentofacial Orthop* 1991;100(4):312-23.
18. Vasir NS, Thompson RT, Davies TM. Dental and skeletal changes following sagittal split osteotomy for correction of mandibular prognathism. *Eur J Orthod* 1991;13(2):134-42.
19. Athanasiou AE. Morphologic and functional implications of the surgical-orthodontic management of mandibular prognathism: A comprehensive review. *Am J Orthod Dentofacial Orthop* 1993;103(5):439-47.
20. Proffit WR, Turvey TA, Phillips C. Orthognathic surgery: A hierarchy of stability. *Int J Adult Orthodon Orthognath Surg* 1996;11(3):191-204.