

Animal bite injuries to the face : A Case Report

Niverso Rodrigues Simão¹, Alexandre Meireles Borba², André Luis Fernandes da Silva², Evanice Menezes Marçal Vieira³, Artur Aburad Carvalhosa³, Matheus Coelho Bandeca⁴, Álvaro Henrique Borges³.

¹Former Oral and Maxillofacial Surgery Resident, Faculty of Dentistry, Universidade de Cuiabá – UNIC, Brazil; ²Staff, Oral and Maxillofacial Surgery Residence Program, Faculty of Dentistry, Universidade de Cuiabá – UNIC, Brazil; ³Professor, Master of Science Program in Integrated Dentistry Sciences. Universidade de Cuiabá – UNIC, Brazil; ⁴Professor, Master of Science Program in Dentistry, UNICEUMA, São Luis – MA, Brazil.

ABSTRACT

Traumatic lacerations to the skin are problems frequently seen and treated by emergency centers around the world. Among all wounds, dog and cat bites are commonly seen. As in many mammals, different species of microorganisms are found in dog and cat mouths with a potential pathological effect to humans, as represented by rabies. The injuries have disfigurement effect with possible psychological repercussion to the patient. This article aimed presenting up to date considerations regarding the management of animal bite injuries to the face, exemplified by a case report that should be the interest of all professions that deal with facial tissues, as dentists do.

Key Words: Animal bites; Dog bites; Face lesions.

How to cite this article: Simão NR, Borba AM, da Silva ALF, Vieira EMM, Carvalhosa AA, Bandeca MC, Borges AH. Animal bite injuries to the face: A Case Report. *J Int Oral Health* 2013; 5(4):68-72.

Source of Support: Nil

Conflict of Interest: None Declared

Received: 29th May 2013

Reviewed: 12th June 2013

Accepted: 22nd June 2013

Address for Correspondence: Dr. Matheus Coelho Bandeca. Rua Operários, 1457, Ponta Grossa, Brazil.
Email: mbandeca@gmail.com

Introduction

Traumatic lesions to the skin are a major problem faced by emergency centers around the world, comprehending around 11 millions attendances yearly. Among these, it is estimated that one to two millions of cases are caused by dog and cat bites. Although correct statistics are not known due to the lack of compulsory report of such injuries, their importance and repercussion should not be underestimated¹⁻⁵.

Dogs, cats, horses, rats and rabbits are animals usually reported as the ones to cause bite in humans⁶. Dogs are responsible for 60% to 80% of such injuries whereas cats respond for 20% to 40%⁷. Superior extremities are afflicted in 45% of cases, lower limbs 25% and the head and neck region in 22% of situations⁴; the face itself might be affected in 10% to 15% cases^{2, 7-9}. Children are the most common victims (around 50% of occasions),

mainly due to provocative behavior displayed by them or because of their low stature, which exposes their face closer to animal's reach^{3, 10-12}.

Injuries caused by animal bites to the face can cause injuries to soft and hard tissues, presented by perforations, lacerations, crushes, avulsion or fractures⁹. An uncountable number of bacteria and virus can be found in such injuries, a reason for a concern regarding infections⁷.

Infected lesions involving noble structures are the causative of about 15 deaths yearly in the United States of America¹³⁻¹⁴. Another problem associated to animal bite injuries is the transmission of human rabies. Over 55.000 cases of human rabies transmitted by dogs occur each year worldwide, which is an endemic problem in Asia and in Africa¹⁴.

Treatment of animal bite lesions consists mainly in adequate wound cleaning in order to diminish the risk of infection as well as the administration of efficient antibiotics⁸. This article aimed presenting up-to-date considerations regarding the management of animal bite injuries to the face, exemplified by a case report

be affected during evaluation; no bone or dental fractures were observed (**Figure 1 B**).

To the complexity of the soft tissue injuries and patient's age, management of the wounds was accomplished under general anesthesia. After proper facial disinfection and preparation of the surgical field

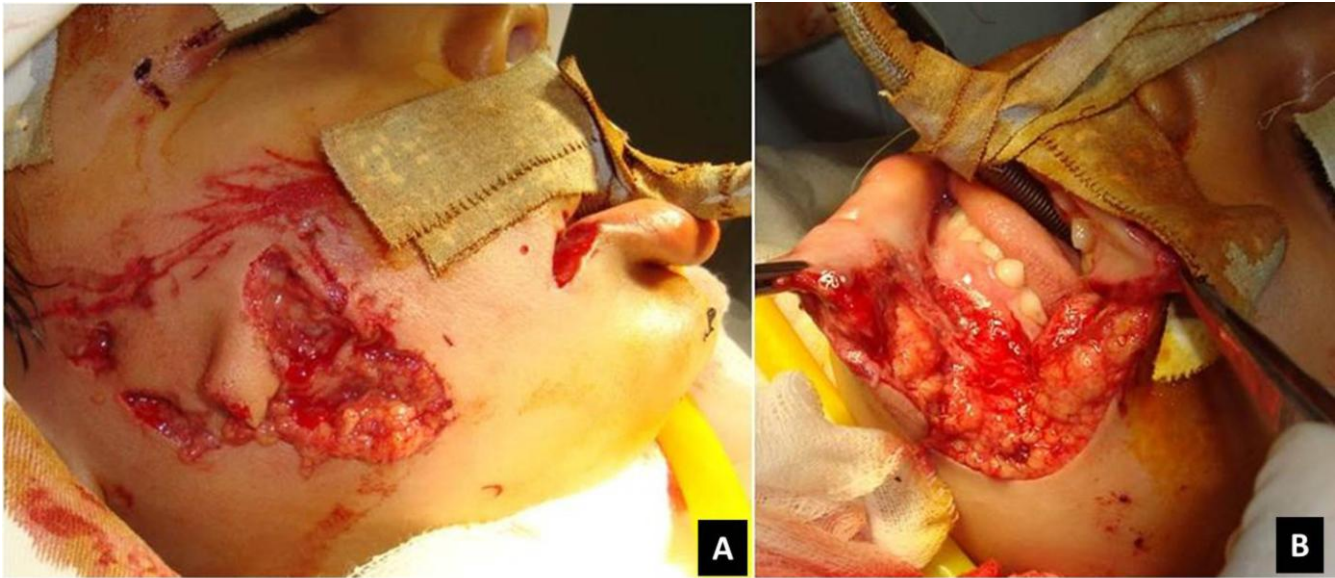


Fig. 1: facial wounds properly exposed and cleaned under general anesthesia. Right cheek laceration (A) and a laceration of the left labial region through the lower labial skin to the mucosa, detaching the ipsilateral labial commissure (B).

treated by oral and maxillofacial surgeons. This knowledge should be the interest of all professions that deal with facial tissues, as dentists do.

Case Report

A Caucasian six-year-old male patient presented to evaluation by the Oral and Maxillofacial service of the Emergency Hospital of the city of Cuiaba, Brazil. He and his parents reported a facial bite caused by their own dog (regularly vaccinated) one hour before. Patient had no neurological/behavioral alterations related to the trauma or history of systemic disease and drug allergies.

Primary evaluation revealed that the patient was lucid, interacting to the emergency team, hemodynamic stable, with normal vital signs. Facial examination displayed some abrasion, a laceration involving the right cheek and a laceration of the left labial region that went through the lower labial skin to the mucosa detaching the ipsilateral labial commissure (**Figure 1 B**). Parotid duct seemed not to

with sterile surgical drapes, the wounds were thoroughly irrigated with saline, minor debridement was performed and sutures were accomplished under meticulous care (5.0 polyglycolic acid absorbable sutures for the muscle and oral mucosa; 6.0 nylon for skin (**Figure 2 A and B**).

Human rabies prevention was accomplished at the same day and three days later, as the aggressor animal (family's dog) was regularly vaccinated. Tetanus prophylaxis was not performed as the patient had recent immunization, according to the national immunization calendar. Amoxicillin associated to clavulanic acid was the choice for antibiotic regimen for seven days. Follow up of the patient did not reveal any sign of infection. The patient lost later follow up and then showed up one year later (**Figure 3 A, B and C**), demonstrating the absence of any impairment to the facial region other than a hypertrophic scar for which his parents refused further treatment at that moment.

Discussion

Most of animal bite injuries are caused by animals of close association to the victims, frequently found to be children^{4, 15}. This type of lesions carries an infection potential and possible psychological harmful effect due to esthetic consequences^{4, 16}.

Epidemiological data indicate that animal bites are prone to occur while patients are at home, during weekends, mostly associated with summer months^{6, 15}.

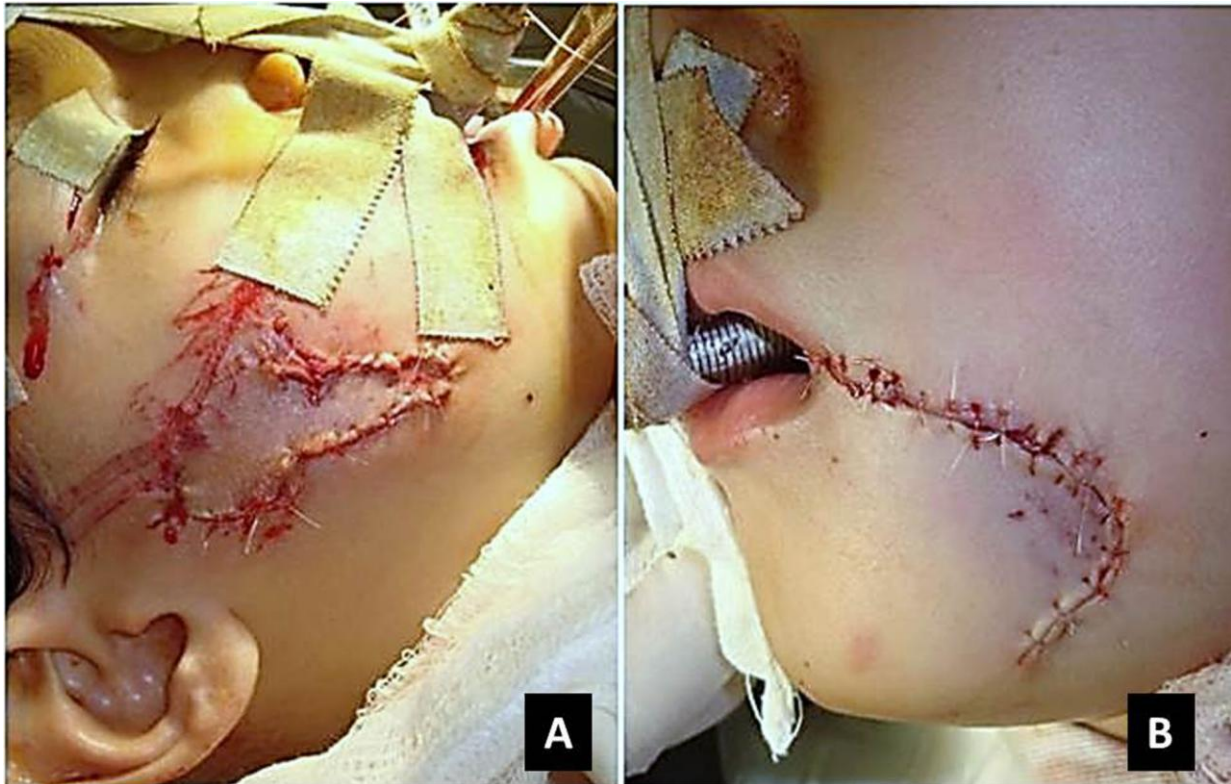


Fig. 2: Primary closure of the wounds at the cheek region (A) and the lower labial region (B).

Initial management is accomplished by a detailed history of the trauma itself and information of patient's medical history including vaccines and immunization profile¹⁷⁻¹⁸.

Diagnosis is performed by a thorough clinical examination, with attention to noble structures as vessels, nerves, salivary glands and ducts, articulations, tendons, cartilage, teeth and bones^{7, 17}. Vulnerable areas of the face are eyelids, lips and nose¹⁹. Some injuries may require surgical flaps or skin grafts for adequate closure. Image exams might help to exclude fractures or foreign bodies associated to the wounds^{2, 7, 17}

Careful cleaning of the wound helps reducing the risk of infection; copious irrigation with saline diminishes the number of microorganisms associated to the wounds without healing process harmful effect^{8, 20-21}. Iodine solution at 1% might be used as well, presenting good bactericide action and low cellular toxicity^{8, 20, 22}.

Debridement is a common practice of such type of injuries but should be performed with caution not to

sacrifice viable tissue, mainly in esthetic areas as the red lip, nose and eyelids⁸⁻⁹. When proper accomplished, debridement might reduce significantly the incidence of infection²⁰. At the past, surgical treatment used to be delayed and secondary intention wound healing was commonly seen. That management was believed to be safer as infection was believed to happen after primary closure²². Nowadays, it is well known that even after

few hours of the trauma, the facial region is richly vascularized so proper wound management and primary closures are possible. When different tissues such skin, muscle and oral mucosa are closed with appropriate material, better esthetic results are obtained and major secondary reconstruction interventions can be avoided²³⁻²⁴.

The incidence of infection associated to animal bite injuries vary from 5% to 30%²⁵. Infections after primary closure at the head and neck region, when associated with adequate antibiotic coverage, occur in 1% of cases²⁶. Common microorganisms found in such wounds are *Pasteurella*, *Staphylococcus Aureus*, *Streptococcus* and *Pasteurella Multocida*, mainly in a polymicrobial pattern^{2-4, 20, 22}. Dog bites also carry the concern of human rabies and tetanus infection since this animal is responsible for 90% of transmission for such diseases in Brazil²⁷. Human rabies is an infectious disease of viral origin that can be transmitted by minimum contact and promoting acute encephalitis

with a mortality rate near to 100%¹⁴. There is no specific treatment for such condition after its onset, being a

prescription of appropriate antibiotic coverage will allow uneventful local and systemic outcome. Health

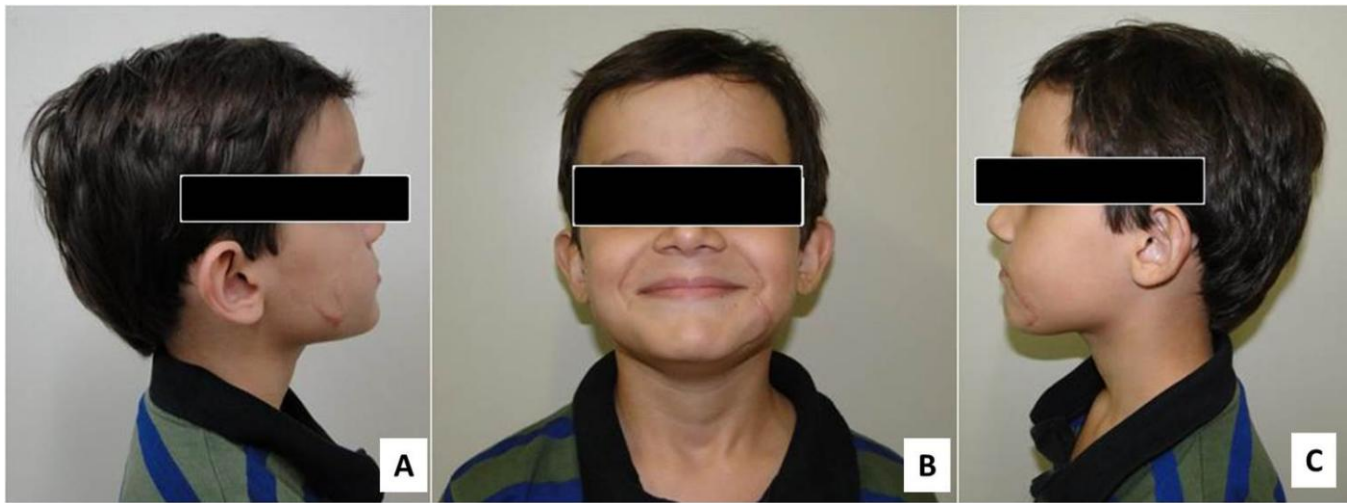

Figure 3. One year follow up at lateral right(A), frontal(B) and lateral left (C) views.

palliative support the only option. Tetanus prevention in children might not be necessary in a child that follows an immunization calendar that covers such condition; adults should have vaccination reinforcement there is a five-year gap since last²⁸.

Injuries caused by cats may present different patterns as their sharp teeth promote a small but deep wound that might allow bacterial growth. On the other hand, dog bites usually present as crush injuries associated with lacerations, especially for bigger dogs^{8, 16, 25}. As expected in other injuries or surgical procedures related to the oral cavity, elimination of possible local infection is paramount and should be among the expertise of dentists²⁹⁻³⁰. Current literature supports the administration of antibiotics in cases of animal bite injuries. The first option antibiotic should be effective against β -lactamase producing bacteria such as commonly seen by *Staphylococcus Aureus* and *Prevotella*. Penicillin derivatives associated with a β -lactamase inhibitor such as the clavulanic acid are usually the first choice but the inhibitor may also be found associated to a cephalosporin^{3, 7-9, 26, 31}. Azithromycin can be considered for patients with penicillin allergic reaction or during⁸⁻⁹.

Conclusion

Proper wound management consisting in thorough irrigation and careful debridement are important to diminish the risk of infection after primary closure, which should be considered for animal bite injuries to the face. The adoption of such protocol might promote good results without the need for major reconstruction procedures, as performed in the past. The adoption of human rabies and tetanus prevention as well as the

professions such dentists, especially those that deal with the maxillofacial region, should be aware of the adequate management of these wounds as patients might be referred to their evaluation and treatment.

References

1. Morgan JP 3rd, Haug RH, Murphy MT. Management of facial dog bite injuries. *J Oral Maxillofac Surg.* 1995;53(4):435-41.
2. Morgan M. Hospital management of animal and human bites. *J Hosp Infect.* 2005;61(1):1-10.
3. Abuabara A. A review of facial injuries due to dog bites. *Med Oral Patol Oral Cir Bucal.* 2006;11(4):E348-50.
4. Ball V, Younggren BN. Emergency management of difficult wounds: part I. *Emerg Med Clin North Am.* 2007;25(1):101-21.
5. DeBoard RH, Rondeau DF, Kang CS, Sabbaj A, McManus JG. Principles of basic wound evaluation and management in the emergency department. *Emerg Med Clin North Am.* 2007;25(1):23-39.
6. MacBean CE, Taylor DM, Ashby K. Animal and human bite injuries in Victoria. 1998-2004. *Med J Aust.* 2007;186(1):38-40.
7. Kramer A, Assadian O, Frank M, Bender C, Hinz P. Working Section for Clinical Antiseptic of the German Society for Hospital H. Prevention of post-operative infections after surgical treatment of bite wounds. *GMS Krankenhhyg Interdiszip.* 2010;5(2).

8. Stefanopoulos PK, Tarantzopoulou AD. Facial bite wounds: management update. *Int J Oral Maxillofac Surg.* 2005;34(5):464-72.
9. Stefanopoulos PK, Tarantzopoulou AD. Management of facial bite wounds. *Dent Clin North Am.* 2009;53(4):691-705, vi.
10. Bernardo LM, Gardner MJ, O'Connor J, Amon N. Dog bites in children treated in a pediatric emergency department. *J Soc Pediatr Nurs.* 2000;5(2):87-95.
11. Lang ME, Klassen T. Dog bites in Canadian children: a five-year review of severity and emergency department management. *CJEM.* 2005;7(5):309-14.
12. Kesting MR, Holzle F, Pox C, Thurmuller P, Wolff KD. Animal bite injuries to the head: 132 cases. *Br J Oral Maxillofac Surg.* 2006;44(3):235-9.
13. Walker T, Modayil P, Cascarini L, Collyer J. Dog bite- fracture of the mandible in a 9 month old infant: a case report. *Cases J.* 2009;2(1):44.
14. Jackson AC. Why does the prognosis remain so poor in human rabies? *Expert Rev Anti Infect Ther.* 2010;8(6):623-5.
15. Akhtar N, Smith MJ, McKirdy S, Page RE. Surgical delay in the management of dog bite injuries in children, does it increase the risk of infection? *J Plast Reconstr Aesthet Surg.* 2006;59(1):80-5.
16. Dwyer JP, Douglas TS, van As AB. Dog bite injuries in children--a review of data from a South African paediatric trauma unit. *S Afr Med J.* 2007;97(8):597-600.
17. Dire DJ, Hogan DE, Riggs MW. A prospective evaluation of risk factors for infections from dog-bite wounds. *Acad Emerg Med.* 1994;1(3):258-66.
18. Presutti RJ. Prevention and treatment of dog bites. *Am Fam Physician.* 2001;63(8):1567-72.
19. Hersant B, Cassier S, Constantinescu G, Gavelle P, Vazquez MP, Picard A, Kadlub N. [Facial dog bite injuries in children: retrospective study of 77 cases]. *Ann Chir Plast Esthet.* 2012;57(3):230-9.
20. Callaham ML. Treatment of common dog bites: infection risk factors. *JACEP.* 1978;7(3):83-7.
21. Sabhaney V, Goldman RD. Child health update. Management of dog bites in children. *Can Fam Physician.* 2012;58(10):1094-6, e548-50.
22. Lackmann GM, Draf W, Isselstein G, Tollner U. Surgical treatment of facial dog bite injuries in children. *J Craniomaxillofac Surg.* 1992;20(2):81-6.
23. McHeik JN, Vergnes P, Bondonny JM. Treatment of facial dog bite injuries in children: a retrospective study. *J Pediatr Surg.* 2000;35(4):580-3.
24. Balamurugan R, Mohamed M, Pandey V, Katikaneni HK, Kumar KR. Clinical and histological comparison of polyglycolic acid suture with black silk suture after minor oral surgical procedure. *J Contemp Dent Pract.* 2012;13(4):521-7.
25. Wolff KD. Management of animal bite injuries of the face: experience with 94 patients. *J Oral Maxillofac Surg.* 1998;56(7):838-43; discussion 43-4.
26. Boillat N, Frochoux V. [Animal bites and infection]. *Rev Med Suisse.* 2008;4(174):2149-52, 54-5.
27. Fleisher GR. The management of bite wounds. *N Engl J Med.* 1999;340(2):138-40.
28. Bothra R, Bhat A, Saxena G, Chaudhary G, Narang V. Dog bite injuries of genitalia in male infant and children. *Urol Ann.* 2011;3(3):167-9.
29. Ogunbodede EO, Fatusi OA, Folayan MO, Olayiwola G. Retrospective survey of antibiotic prescriptions in dentistry. *J Contemp Dent Pract.* 2005;6(2):64-71.
30. Chkoura A, Elwady W, Taleb B. Surgical management of a cutaneous sinus tract: a case report and review of the literature. *J Contemp Dent Pract.* 2010;11(5):49-55.
31. Cummings P. Antibiotics to prevent infection in patients with dog bite wounds: a meta-analysis of randomized trials. *Ann Emerg Med.* 1994;23(3):535-40.