

Dento-Alveolar Distraction Osteogenesis for rapid Orthodontic Canine Retraction

Naveen Kumar¹, GS Prashantha², Sudhir Raikar³, Krishnappa Ranganath⁴, Silju Mathew⁵, Sandeep Nambiar⁶

¹Reader, Department of Orthodontics & Dento-facial Orthopaedics, M S Ramaiah Dental College & Hospital, Bangalore, Karnataka, India; ²Professor, Department of Orthodontics, M S Ramaiah Dental College, Bangalore, Karnataka, India; ³Dental health officer, CHC, Sankeshwar, Belgaum, Karnataka, India; ⁴Professor, Department of Oral Surgery, M S Ramaiah Dental College, Bangalore, Karnataka; ⁵Professor & Head, Department of Orthodontics, M S Ramaiah Dental College, Bangalore, Karnataka; ⁶Reader, Department of Orthodontics, M S Ramaiah Dental College and Hospital, Bangalore.

ABSTRACT

Background: The objectives of this study were to evaluate the rate of canine distalization by segmental alveolar distraction method in first premolar extraction cases, to evaluate the displacement of the canine and first molar teeth, to assess the effects of the procedure on the pulpal vitality of the canines, and to determine the amount of root resorption in retracted canines.

Materials & Methods: The sample of the study consisted of 20 teeth in 7 patients (five females and two males, mean age 18.5 years). After the osteotomy procedure distractor was fixed. After 3 days of consolidation period, the distractor was activated 3 quarter turns per day(0.75 mm/day) till the canines comes in contact with second premolar. An electrical vitality test was applied before and after the distraction procedure and during the follow-up period.

Results: The mean distal retraction of canines was 7.262 ± 0.4864 mm. The distal displacement of the canine was mainly a combination of tipping and translation. The mean distraction procedure was completed in 14.60 ± 1.536 days. The duration of retraction was less for mandibular canine compared to maxillary canine. The mean posterior anchorage loss was mean 0.50 ± 0.688 mm. The amount of root resorption that occurred during distraction was clinically insignificant. None of the teeth reacted negatively to the electrical vitality test that was performed 6 months after the completion of the distraction procedure. There was no clinical sign of discoloration or pulpal pain in any tooth.

Conclusion: With dentoalveolar distraction, as canines can be fully retracted in 12 to 16 days, the non-compliance patients, patients with root-shape malformations, periodontal problems, or ankylosed teeth will benefit from this technique. The anchorage teeth can withstand the retraction forces better with no anchorage loss, and without clinical or radiographic evidence of root resorption, ankylosis, periodontal problems, and soft tissue dehiscence. This technique reduces orthodontic treatment duration by 6 to 9 months in patients who need extraction, with no need for any sort of anchorage reinforcement.

Key Words: Distraction Osteogenesis, canine Retraction, pulp vitality.

How to cite this article: Kumar N, Prashantha GS, Raikar S, Ranganath K, Mathew S, Nambiar S. Dento-Alveolar Distraction Osteogenesis for rapid Orthodontic Canine Retraction. *J Int Oral Health* 2013; 5(6):31-41.

Source of Support: Nil

Conflict of Interest: None Declared

Received: 11th August 2013

Reviewed: 15th September 2013

Accepted: 14th October 2013

Address for Correspondence: Dr. Naveen Kumar. Department of Orthodontics & Dento-facial Orthopaedics, M S Ramaiah Dental College & Hospital, Bangalore, Karnataka, India. Phone: +91 – 9886924923.
Email: naveen81ortho@gmail.com

Introduction

Distraction osteogenesis is a process of inducing new bone by mechanical stretching of the preexisting skeletal tissue.¹ It has gained its wide spread recognition in orthopedic surgery as an effective means of bone lengthening, deformity correction and filling large diaphyseal defects. Recently distraction osteogenesis has been extensively applied to the craniofacial complex and is increasingly becoming a viable treatment option in the correction of craniofacial deformities.

Distraction osteogenesis was used as early as 1905 by Codivilla² and later popularized by clinical and research studies by Illizarov³ in Russia. Guerrero⁴ in 1990 and MaCarthy et al⁵ in 1992 performed distraction osteogenesis in human mandible. Since then it has been applied to various bones of craniofacial skeleton.⁶ Liou and Huang⁷⁻⁹ first investigated and applied this concept to orthodontic tooth movement and performed rapid canine retraction through distraction. External devices were initially used for distraction osteogenesis. The devices for intraoral application were introduced shortly afterward and newer applications have been fostered. These intraoral devices can be tooth borne,^{10, 11} bone borne¹² or both has gained popularity as they are much simpler and more patient acceptable.

Most orthodontic patients have some crowding or proclination and need extractions. The first phase of treatment for premolar extraction patients is the distal movement of the canine with conventional orthodontic treatment techniques. Canine retraction phase usually lasts 6 to 8 months.

The duration of treatment is one of the problems that orthodontic patients complain, especially adult patients. To address this problem the technique of Dentoalveolar distraction osteogenesis (DAD) has been developed.

With the present technique of rapid orthodontic canine retraction through distraction osteogenesis by Rehakisnisci and Halukiseri¹³, the dentoalveolus itself is designed as a bone transport segment for posterior movement. Vertical osteotomies are performed around the root of the canine teeth followed by splitting of spongy bone around it. Therefore the design of

surgical technique itself does not rely on the periodontal stretching which obviates overloading and stress accumulation in this tissue, which was the drawback of the previous attempts of canine distraction through periodontal ligament described by Eric Liou and Shing Huang.

Thus this study is undertaken to evaluate the outcomes of distraction osteogenesis technique in rapid Orthodontic tooth movement.

Objectives:

The objectives of this study were

1. To evaluate time taken for retracting canine.
2. To determine and quantify anchor loss of molar and premolar
3. To asses pulp vitality of retracted canine.
4. To evaluate root resorption of retracted canine.
5. To evaluate overall time taken to complete treatment.

Materials and Methods

The patients presenting with Class I or class II division I malocclusion who needed orthodontic treatment with fixed appliances and tooth extractions attending Department of Orthodontics and Dentofacial orthopaedics of M.S. Ramaiah dental college were selected for this study. All patients were in the permanent dentition and had moderate to severe crowding or increased overjet at the start of treatment. Co-operative patients with healthy periodontium were included in the study. Medically compromised patients, Syndromic patients and patients with radiographic evidence of less than 5 mm between maxillary sinus and canine were excluded. The study sample consisted of 20 maxillary and mandibular canines in 7 adult subjects. The treatment procedure was explained in detail to all patients and informed consent was obtained before the procedure.

Pre and post treatment orthodontic models, cephalometric and panoramic radiographs as well as standard photographs of all the patients were obtained. Periapical radiographs of the canines were taken before osteotomy procedure and repeated after six months of distraction period to observe the root

resorption and the changes in the periodontal ligament and alveolar bone.

METHOD OF DISTRACTOR CONSTRUCTION

(Figure 1: Construction of distractor,
Figure 2: Construction of distractor,
Figure 3: Construction of distractor)

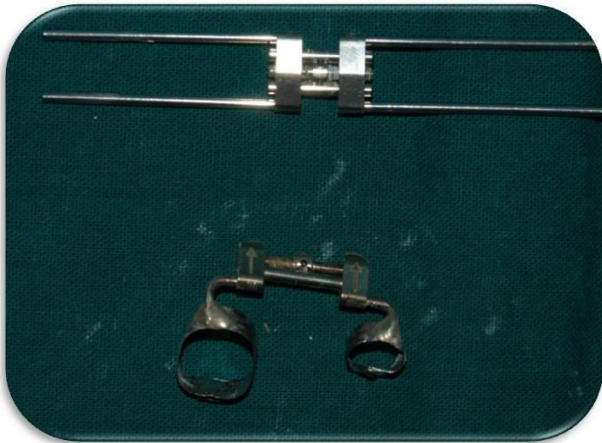


Figure 1: Construction of Distractor.

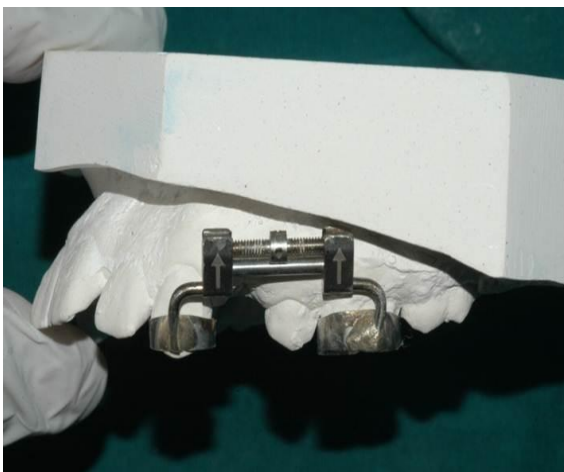


Figure 2: Construction of Distractor.

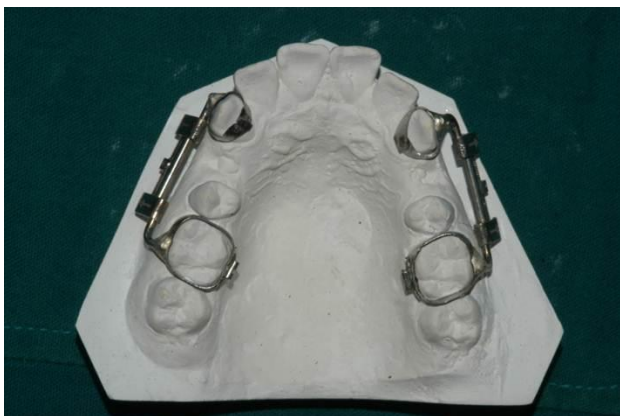

Figure 3: Construction of Distractor.

Separators were placed mesial and distal of canine as well as molars.¹⁴ Selection of bands was done three days after placing separators. Bands were transferred into the impression material and a working cast obtained. Custom made distractor was fabricated by modifying 13mm hyrax screw. Distractor was soldered to bands. After the osteotomy procedure distractor was fixed to molar and canine with help of glass ionomer cement. After 3 days of consolidation period activation of distractor was done 3 quarter turns per day (0.75mm/day).

Distraction was continued till canines comes in contact with the second premolars. The distractor was then removed and fixed orthodontic appliance treatment was immediately initiated for levelling and aligning both dental arches. Consolidation was done with figure of 8 ligatures and was kept at least 3 months after completion of the DAD procedure to avoid mesial movement of the canine. The patient was advised to maintain good oral hygiene during DAD procedure and fixed appliance orthodontic therapy.

DISTRACTION PROTOCOL

The distraction procedure was initiated after 3 days of a latency period after surgery.¹⁴ The distraction device was activated once a day at a rate of 0.75mm/d. After the completion of the distraction procedure, a consolidation period of 2 week was adapted, and then the treatment was continued with conventional fixed appliances.

FLAP DESIGN

(Figure 4: Flap design)

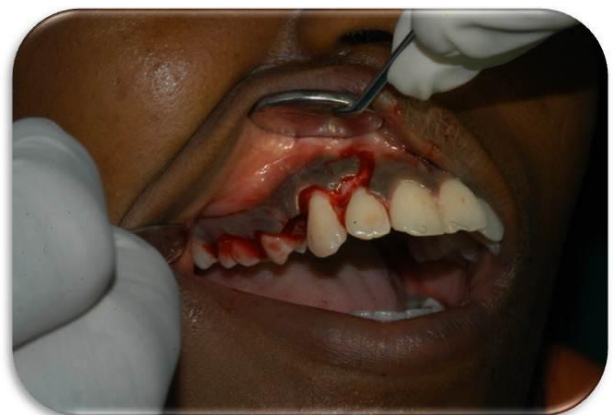

Figure 4: Flap Design.

Crevicular incisions^{14, 15} were made extending from the distal interdental papilla of the first molar to the distal interdental papilla of the lateral incisor on the corresponding side. In addition, a vertical releasing incision beginning mesial to the distal interdental papilla of the lateral incisor at the vestibule was made. A mucoperiosteal flap was elevated 6 mm above the canine and first premolar to allow for the planned osteotomy.

OSTEOTOMY PROCEDURE

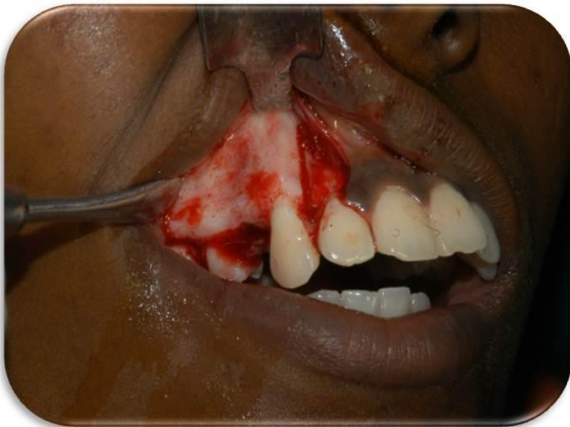

Figure 5: Osteotomy Cuts.

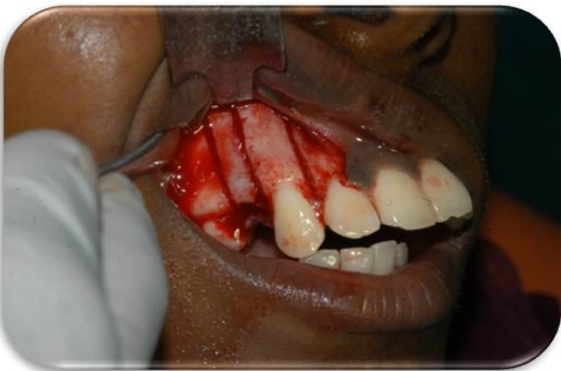

Figure 6: Osteotomy Cuts.

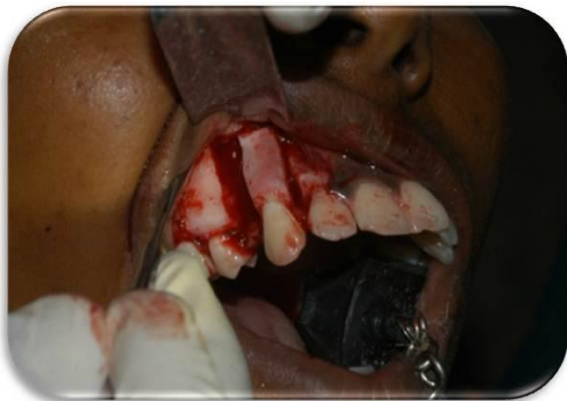

Figure 7: Osteotomy Cuts.

(Figure 5: Osteotomy procedure, Figure 6: Osteotomy procedure, Figure 7: Osteotomy procedure)

The first premolar was extracted after the flap preparation, and the buccal wall of the extraction socket was removed with osteotomes.^{14,15} An osteotomy line was determined between the buccal root apex of the first premolar and canine apex on the panoramic radiograph, taking magnification into consideration. A reference point was formed 5 mm above the canine apex in the alveolar bone with a round bur, and new reference points were constructed mesial and distal to the initial reference point coronally to gain minimal space in the osteotomy line, all reference points were connected with a osteotome.

The palatal wall of the extraction socket of the first premolar was ground, and the depth of the extraction socket of the first premolar was increased with a round bur to allow for the sliding of the distracted dentoalveolar segment. The osteotomy depth was increased with interdental osteotomes. Afterwards, the osteotomy procedure was continued by advancing through the extraction socket of the first premolar with osteotomes with curved tips and then completed by a final osteotomy extending coronally from the apical region of the canine on the palatal side.

(Figure 8: Distractor in place, Figure 9: 4th day of distraction, Figure 10: 12th day of distraction, Figure 11: Removal of distractor, Figure 12: Consolidation with orthodontic appliance, Figure 13: Completion of orthodontic treatment, Figure 14: Immediate post distraction OPG)

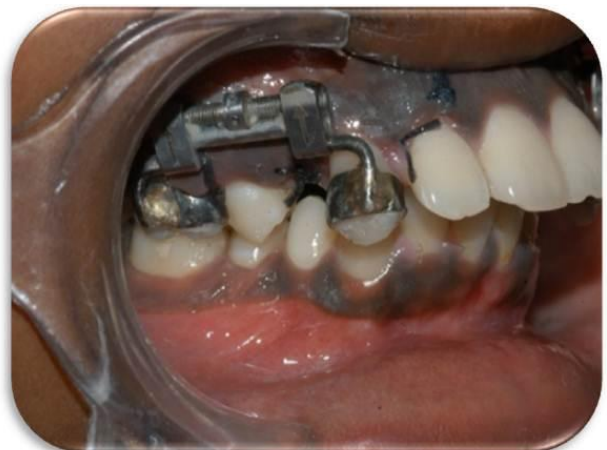

Figure 8: Distractor in place.

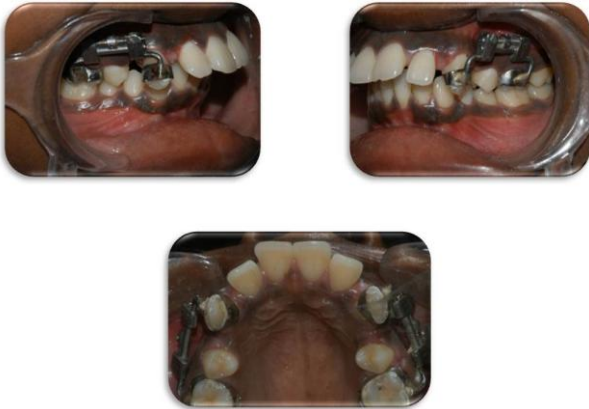

Figure 9: Fourth Day of Distraction.

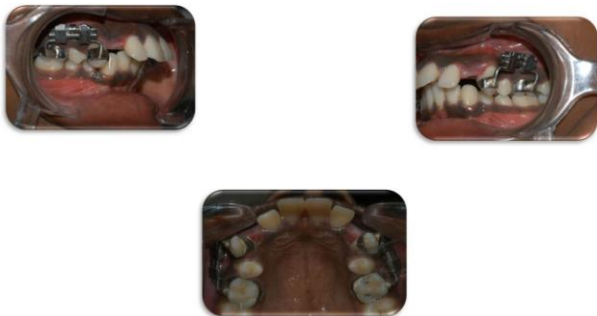

Figure 10: Twelfth Day of Distraction.

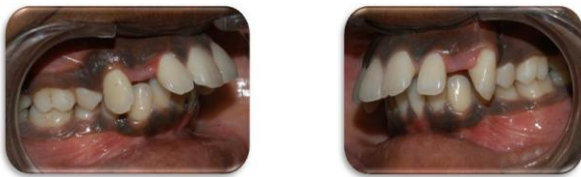

Figure 11: Removal of Distractor.

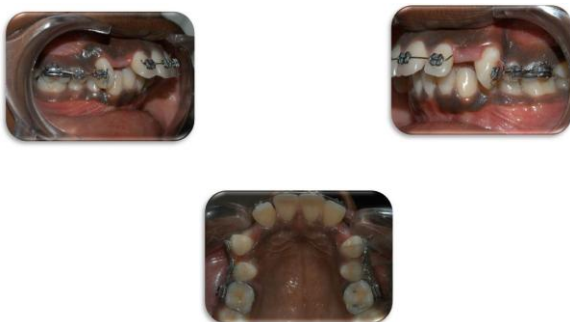

Figure 12: Consolidation with Orthodontic Appliance.

VITALITY

An electrical vitality test was performed before and after the distraction procedure and 6 months after the completion of the procedure with an electronic pulp tester.¹⁴ The probe of the pulp tester was placed on the occlusal or incisal one-third of the buccal enamel

surface of the tooth, and the current was increased gradually. Each patient was observed for signs of pain, and then the corresponding number on the scale was registered.

PERIAPICAL RADIOGRAPHS

To evaluate the amount of root resorption, periapical radiographs were taken for all canines just before the distraction and 6 months after the completion of the procedure with the same periapical x-ray machine (CCX Digital Type 70, Trophy Radiologie, Paris, France).

All radiographs were taken by parallel long cone technique.¹⁶ An effort was made to maintain a minimum distance between the tooth and film to avoid magnification and to position the film parallel to the long axis of the tooth to avoid elongation. To evaluate the amount of apical and lateral root resorption, the scale described by Liou andHuang⁸ was used.

The apical root resorption was assessed by the following scores.¹⁶

- 0 = No apical root resorption.
- 1 = Slight blunting of the canine root apex.
- 2 = Moderate resorption of the root apex beyond blunting and up to one fourth of the root length.
- 3 = Excessive resorption of the root apex beyond one fourth of the root length

The lateral root resorption on the distal side of the canine root was assessed according to the following scores:

- 0 = Smooth lateral root surface and periodontal ligament.
- 1 = Slightly irregular lateral root surface; not beyond one third of the dentine width between the distal side periodontal ligament and pulp chamber.
- 2 = Moderate irregular lateral root surface beyond one third and up to two thirds of the dentine width between the distal side periodontal ligament and pulp chamber.
- 3 = Excessive irregularity of the lateral root surface beyond two thirds of the dentine width between the distal side periodontal ligament and pulp chamber.

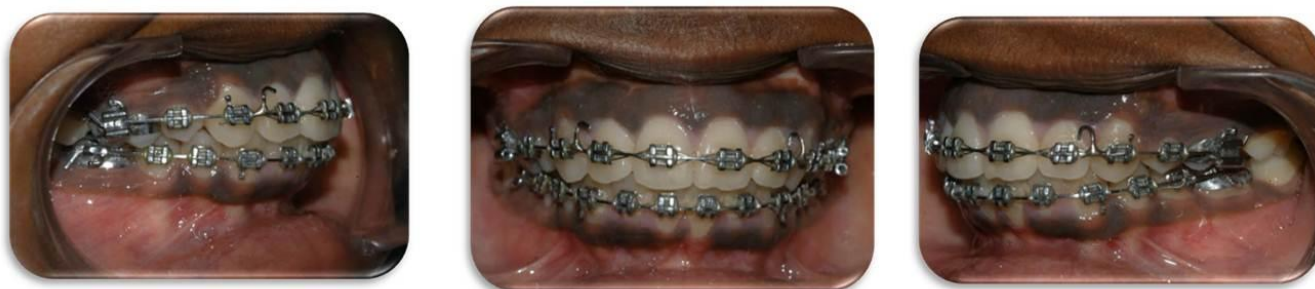

Figure 13: Completion of Orthodontic Treatment.

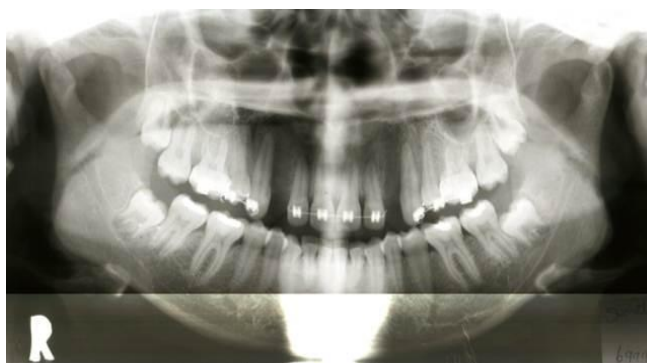


Figure 14: Immediate Post-Distraction OPG.

MODEL ANALYSIS

(Figure 15: Pre-distraction model analysis.

Figure 16: Post-distraction model analysis.)

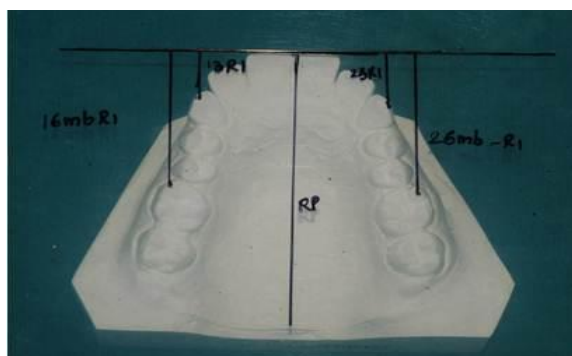


Figure 15: Pre-distraction Model Analysis.

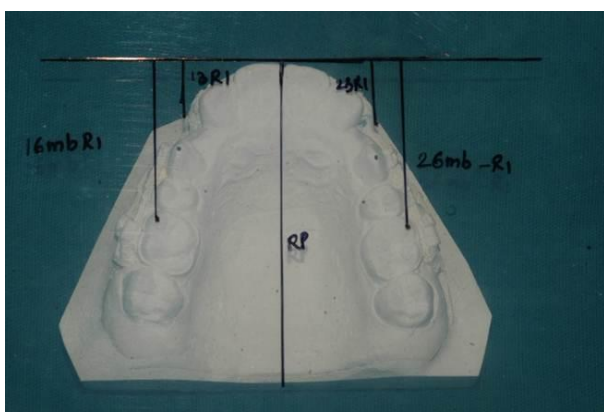


Figure 16: Post-Distraction Model Analysis.

To evaluate the amount of canine movement and posterior anchorage loss, Alginate impressions were taken before starting distraction and after 6 months post distraction on all seven patients and poured in hard stone. A total of fourteen study casts were obtained. The posterior anchorage loss and the amount of canine movement in the anteroposterior direction were assessed by determining the location of maxillary raphe by using two predetermined reference points as described by Hoggan and Sadowsky.¹⁵

The mandibular midline was marked on the study models by transferring the maxillary raphe on these models. The maxillary (R1) and mandibular (R2) reference planes were formed by plotting tangents to the interdental contact points of the upper and lower central incisors (R1 and R2 were constructed to intersect Rp vertically). The perpendicular distances from the cusp tips of the upper and lower canines and the mesiobuccal cusp tip of the first molars to the reference line were measured.

A transparent grid was used to measure the amount of canine and molar movements in the model analysis. To evaluate the data obtained from the model analysis, descriptive statistical methods were used.

To draw R2: draw the arch form on a template

overlying the cusp tips of posteriors and incisal edges of anterior teeth in the mandibular arch. Then draw a tangent to the arch perimeter passing between the central incisors.

Reference points and lines used for the measurements performed on the study casts.

R1- indicates the perpendicular distance from the cusp tip of the upper right canine to line R1.

23-R1, the perpendicular distance from the cusp tip of upper left canine to line R1.

33-R2, the perpendicular distance from the cusp tip of lower right canine to line R2.

43-R2, the perpendicular distance from the cusp tip of lower left canine to line R2.

16mb-R1, the perpendicular distance between the mesiobuccal cusp tip of the upper right first molar and line R1.

26mb-R1, the perpendicular distance between the mesiobuccal cusp tip of the upper left first molar and line R1.

36mb-R2, the perpendicular distance between the mesiobuccal cusp tip of the lower right first molar and line R2.

46mb-R2, the perpendicular distance between the mesiobuccal cusp tip of the Lower left first molar and line R2.

Results

Distal displacement of canines:

(Table 1: Distal displacement of canines)

The distal displacement of canines shown ranged from 6.37 to 8.28 mm (mean 7.262 \pm 0.4864). The distal displacement of the canine was mainly a combination of tipping and translation. Patients reported minimal to moderate discomfort, especially during the first 2 days after surgery, and edema was observed in some patients.

Duration of Distraction:

(Table 2: Duration of Distraction)

The distraction procedure was completed in 12 to 16 days.(mean 14.60 \pm 1.536). Duration of distraction was less for mandibular canine compared to maxillary canine. Average of 14 day for mandibular canine and

for maxillary canine average was 14.86 days were taken.

Posterior anchor loss:

(Table 3: Posterior anchor loss)

The posterior anchorage loss ranged from 0 to 2mm (mean 0.50 \pm 0.688). The average mesial movement of right molar was 1 \pm 1.0 and left molar was 0.67 \pm 0.57 in mandibular arch.

The average mesial movement of right molar was 0.43 \pm 0.787 and left molar was 0.29 \pm 0.488 in maxillary arch.

Root resorption:

(Table 4: Root resorption)

It was observed that the amount of root resorption that occurred during distraction was clinically insignificant as shown in table.

(Table 5: Mean distribution)

Vitality post distraction:

It was observed that all the 20 teeth in study sample were vital before the distraction. None of teeth reacted negatively to the electrical vitality test that was performed 6 months after the completion of the distraction procedure. There was no clinical sign of discoloration or pulpal pain in any tooth.

Discussion

Presently orthodontics is synonym with long treatment and cumbersome delays. Orthodontists have always strived hard for new techniques to reduce the overall treatment time, with minimum patient co-operation. Canine distraction was introduced as an alternative treatment to retract the canines in minimum possible period of 12 to 16 days, thus avoiding taxing the anchorage on molars because the canines are retracted within the lag phase of molars. Orthodontic tooth movement is a process in which a mechanical force is applied to induce alveolar bone resorption on the pressure side, and alveolar bone deposition on tension side. Conventional orthodontic treatments with either fixed or removable appliances rely on this kind of

Table 1: Distal Displacement of Canines

	N	Mean	SD	Minimum	Maximum
RIGHT UPPER CANINE	7	7.434	0.4208	6.81	8.18
LEFT UPPER CANINE	7	7.300	0.4783	6.74	8.28
RIGHT LOWER CANINE	3	7.103	0.7670	6.37	7.90
LEFT LOWER CANINE	3	6.930	0.3601	7.25	7.25
TOTAL	20	7.262	0.4864	6.37	8.28

Table 2: Duration of Distraction

	N	Mean	SD	Minimum	Maximum
RIGHT UPPER CANINE	7	14.86	0.4208	12	16
LEFT UPPER CANINE	7	14.86	1.574	12	16
RIGHT LOWER CANINE	3	14.00	1.732	12	15
LEFT LOWER CANINE	3	14.00	1.732	12	15
TOTAL	20	14.60	1.536	12	16

Table 3: Posterior Anchor Loss

	N	Mean	SD	Minimum	Maximum
Right Upper Canine	7	0.43	0.787	0	2
Left Upper Canine	7	0.29	0.488	0	1
Right Lower Canine	3	1.00	1.000	0	2
Left Lower Canine	3	0.67	0.577	0	0
Total	20	0.50	0.688	0	2

Table 4: Evaluation of Root Resorption

	Apical		Total
	Absent	Present	
Right Upper Canine	6	1	7
	85.7%	14.3%	100.0%
Left Upper Canine	4	3	7
	57.1%	42.9%	100.0%
Right Lower Canine	3	0	3
	100.0%	0	100.0%
Left Lower Canine	3	0	3
	100.0%	0	100.0%
Total	16	4	20
	80.0%	20.0%	100.0%

Table 5: Mean Distribution

	N	Mean	SD	Median	Min.
Distance (mm)	20	7.262	0.4864	6.37	8.28
Distraction time (Days)	20	14.60	1.536	12	16
Anchor Loss (mm)	20	0.500	0.688	0	2

biological tooth movements. Using conventional techniques, biological tooth movement can be achieved at a limited rate. Individual factors such as optimum force turn over in periodontal ligament, and bone metabolism plays a role in determination of rate of

tooth movement. The time required for tooth movement within the alveolar bone may lengthen the overall orthodontic treatment time. Classically, canine tooth distalization occurs at a rate of 1mm per month. Therefore, cases in which premolar extractions are

deemed necessary as part of orthodontic treatment plan, the canine distalization period takes 6-8 months. Minimizing the orthodontic treatment time and controlling the anchorage loss are common aims of research. Rapid canine distalization is a cornerstone for these goals and was first introduced by Liou and Huang (1998).⁷ Studies of rapid canine distalization are limited because the technique is primarily indicated in adults who require maximum anchorage control. The lag period concept is used for controlling the anchorage of posterior teeth, and the philosophy of canine distraction can be summarized as rapid distalization of the canines through the extraction socket while the posterior teeth are still in a lag period and before the orthodontic forces causes undesired root resorption.

The regular rate of osteogenesis in orthodontic tooth movement during canine retraction is about 1mm per month. However, it has been shown that by orthodontically moving a tooth into a fibrous bone tissue just created by distraction osteogenesis, the orthodontic tooth movement could be as much as 1.2mm per week. At the time of first premolar extraction, the interseptal bone distal to the canine was undermined with a bone bur, grooving vertically inside the extraction socket along the buccal and lingual sides and extending obliquely toward the socket base. Then, a tooth-borne, custom made, intraoral distraction device was placed to distract the canine distally into the extraction space. It was activated 0.5 to 1.0 mm/day immediately after the extraction. The anchor units were the second premolar and first molar. Both the upper and lower canines were distracted bodily 6.5 mm into the extraction space within 3 weeks. New alveolar bone was generated and remodelled rapidly in the mesial periodontal ligament of the canine during and after the distraction. It became mature and indistinguishable from the native alveolar bone 3 months after distraction. During the distraction, the radiographic examination revealed that apical or lateral surface root resorption of the canine was minimal.

Liou et al (2000)⁹ concluded that a tooth can be moved into the fibrous new bone created by the distraction process at a rapid rate, so the best time to move tooth is immediately after the end of distraction. Iseri and

Kisnisci⁶ described and used a new technique of rapid canine retraction using the principles of distraction osteogenesis (DAD). With this new technique, osteotomies are made around the canine tooth for rapid tooth movement within the dentoalveolar segment using the principles of distraction osteogenesis.

The surgical procedure of corticotomy-assisted orthodontics includes vestibular mucosal incisions and corticotomies. In DAD, mucosal incisions and osteotomies are made only on the vestibular side of the alveolar bone, and the palatal mucosa, and palatal bone remain untouched, thus maintaining adequate blood supply for the transport dentoalveolar segment that includes the canine teeth.

As was mentioned in results, the canines moved at range of 6.37 to 8.28 mm distally. Although the distractor was designed with a hyrax screw and was placed as high as possible on the buccal side of the canine tooth, some amount of tipping was observed. This can be attributed to application of the force occlusal to the centre of resistance of the canine tooth caused by anatomic limitations of the vestibular sulcus. Patients with first premolar extraction usually need effective posterior anchorage control, especially in maximum and moderate anchorage cases. Thus, extraoral or intraoral appliances are used to maintain adequate anchorage. The use of extraoral appliances (eg, headgear) sometimes causes cooperation problems, and failing use of these appliances results in anchorage loss. Use of mini implants has become popular in past years to maintain anchorage and to perform molar distalization and canine retraction. Although orthodontic mini implants are good alternatives to conventional types of extraoral or intraoral anchorage appliances, no system described in the literature can achieve rapid tooth movement. In the present study, the canines retracted in 12 to 16 days without the use of extraoral or intraoral anchorage appliances. Molar teeth did not show clinically significant angular or linear changes, indicating the absence of anchorage loss during orthodontic tooth movement. The hyalinised tissue on the compression side must be undermined with indirect resorption. This period usually lasts 2 or 3 weeks.¹ In our study, rapid canine retraction with DAD was achieved in 12 to 16

days, which is a minimal period for molars to move to the mesial. Vertical corticotomies were performed around the root of the canine teeth, followed by splitting of the spongy bone surrounding it. The design of the surgical technique does not rely on periodontal stretching, and this prevents overloading and stress accumulation on the periodontal tissues. Because the tooth is moved within the alveolar segment, the risk of harmful side effects on the surrounding hard and soft tissues is eliminated. Therefore, no clinical and radiographic evidence of root fracture, root resorption, ankylosis, soft tissue dehiscence, or loss of vitality was observed in canine teeth at the end of DAD and orthodontic treatment. The results of the radiographic examination revealed no clinically significant difference in the findings regarding root resorption. In addition, the apical and lateral root resorption that occurred during the study was clinically insignificant. This can be explained by the fact that rapid canine distalization was completed in a rather short period of time, which was inadequate for root resorption to occur. It is generally accepted that the best way to minimize root resorption is to complete the tooth movement in a short time. Root resorption begins 2 to 3 weeks after the orthodontic force is applied and can continue for the duration of force application. Full retraction of the canines with DAD occurred in 12 to 16 days in our study, an extremely short time for root resorption to begin. The pulp-vitality test is not a reliable technique when performed during orthodontic tooth movement. Moreover, no color change was observed in any teeth during the observation period of this study. Findings of our study indicate that the distal movement of the canines is a combination of tipping and translation. This means that the crown moves more than the root apex. The pulp tissues of the teeth will remain vital under controlled rapid stretching. Therefore, observed tipping of the canines might be an advantage with regard to pulp vitality during rapid tooth movement with DAD. However, further investigation of pulp vitality is needed in patients subjected to rapid tooth movement with dentoalveolar distraction. Our clinical observations support the findings of that experimental study and might provide an example to relieve severe dental crowding and overjet in an extremely short time.

However, systematic clinical and experimental research studies are still needed.

Conclusion

With dentoalveolar distraction, as canines can be fully retracted in 12 to 16 days, the patients with compliance problems, patients with root-shape malformations, periodontal problems, or ankylosed teeth will benefit from this technique. With this technique, anchorage teeth can withstand the retraction forces better with no anchorage loss, and without clinical or radiographic evidence of complications such as root resorption, ankylosis, periodontal problems, and soft tissue dehiscence. The dentoalveolar distraction technique reduces orthodontic treatment duration by 6 to 9 months in patients who need extraction, with no need for any sort of anchorage reinforcement. Results achieved in this study cannot be validated, unless study is done on a bigger sample size. The purpose of this study was to give an insight on distraction osteogenesis technique in fastening the orthodontic tooth movement and to extend the scope in regard to research. However rapid canine distalization through segmental alveolar distraction could be considered as a clinically efficient method that significantly reduces the overall treatment time without causing any serious discomfort or damage to the patient in selected cases.

References

1. Annino DJ, Goguen LA, Karmody CS. Distraction Osteogenesis for reconstruction of mandibular symphyseal defect. *Arch Otolaryngol Head Neck Surg* 1994;120:911-6.
2. Codivilla A. On the means of lengthening, in the lower limbs, the muscles and tissue which are shortened through deformity. *Am J Orthop Surg* 1905;2:353.
3. Ilizarov GA. The tension-stress effect on the genesis and growth of tissues part I the influence of stability of fixation and soft tissue preservation. *Clin Orthop Relat Res* 1989;238:249-81.
4. Guerrero CA, Bell WH, Contasti GI, Rodriguez AM. Mandibular widening by intraoral distraction osteogenesis. *Br J Oral Maxillofac Surg* 1997;35(6):383-92.

5. McCarthy JG, Schreiber J, Karp N, Thorne CH, Grayson H. Lengthening the human mandible by gradual distraction. *Plast Reconstr Surg* 1992;89:1-10.
6. Işeri H, Kişnişci R, Bzizi N, Tüz H. Rapid canine retraction and orthodontic treatment with dentoalveolar distraction osteogenesis. *Am J Orthod Dentofacial Orthop* 2005;127:533-41.
7. Liou EJ, Huang CS. Rapid canine retraction through distraction of the periodontal ligament. *Am J Orthod Dentofacial Orthop* 1998;114:372-82.
8. Liou EJ, Huang CS. Rapid canine retraction using distraction of the periodontal ligament. In: Samchukov ML, Cope JB, Cherkashin AM. *Craniofacial Distraction Osteogenesis*. St Louis, MO: Mosby; 2001. p. 461-74.
9. Liou EJ, Figueroa AA, Polley JW. Rapid orthodontic tooth movement into newly distracted bone after mandibular distraction osteogenesis in a canine model. *Am J Orthod Dentofacial Orthop* 2000;117:391-8.
10. Block MS, Cervini D, Chang A, Gottsegen GB. Anterior maxillary advancement using Tooth-supported distraction osteogenesis. *J Oral Maxillofac Surg* 1995;53(5):561-5.
11. Block MS, Chang A, Crawford C. Mandibular alveolar ridge augmentation in the Dog using distraction osteogenesis. *J Oral Maxillofac Surg* 1996;54(3):309-14.
12. Mommaerts MY. Bone anchored intraoral device for transmandibular distraction. *Br J Oral Maxillofac Surg* 2001;39(1):8-12.
13. Kişnişci RS, Işeri H, Tüz HH, Altug AT. Dentoalveolar distraction osteogenesis for rapid orthodontic canine retraction. *J Oral Maxillofac Surg* 2002;60(4):389-94.
14. Sukurica Y, Karaman A, Gürel HG, Dolanmaz D. Rapid Canine Distalization through Segmental Alveolar Distraction Osteogenesis. *Angle Orthod* 2007;77(2):226-36.
15. Işeri H, Kişnişci R, Bzizi N, Tüz H. Rapid canine retraction and orthodontic treatment with dentoalveolar distraction osteogenesis. *Am J Orthod Dentofacial Orthop* 2005;127:533-41.
16. Sharpe W, Reed B, Subtelney JD, Polson A. Orthodontic relapse, apical root resorption and crestal alveolar bone level. *Am J Orthod Dentofacial Orthop* 1987;91:252-8.
17. Hoggan BR, Sadowsky C. The use of palatal rugae for the assessment of anteroposterior tooth movements. *Am J Orthod Dentofacial Orthop* 2001;119:482-8.