

Quantitative Assessment of Stromal Myofibroblasts in Odontogenic Cysts: A Comparative Immunohistochemical Study

Mahesh H Gabhane¹, Suyog D Tupsakhare¹, Gaurav P Agrawal², Mahesh M Ahire³, Priyanka N Kadoo⁴, Shrikant R Sonune²

Contributors:

¹Reader, Department of Oral Pathology and Microbiology, SMBT Dental College and Hospital, Sangamner, Maharashtra, India;

²Senior Lecturer, Department of Oral Pathology and Microbiology, SMBT Dental College and Hospital, Sangamner, Maharashtra, India; ³Reader, Department of Periodontics and Implantology, SMBT Dental College and Hospital, Sangamner, Maharashtra, India; ⁴Senior Lecturer, Department of Oral Pathology and Microbiology, Swargiya Dadasaheb Kalmegh Smruti Dental College and Hospital, Nagpur, Maharashtra, India.

Correspondence:

Dr. Gabhane MH. Reader, Department Oral Pathology and Microbiology, SMBT Dental College and Hospital, Sangamner, Maharashtra, India. Phone: +91-9890282031. Email: dr.mack0385@gmail.com

How to cite the article:

Gabhane MH, Tupsakhare SD, Agrawal GP, Ahire MM, Kadoo PN, Sonune SR. Quantitative assessment of stromal myofibroblasts in odontogenic cysts: A comparative immunohistochemical study. J Int Oral Health 2015;7(10):49-52.

Abstract:

Background: Myofibroblasts (MF) are fibroblasts having features like smooth muscle. Characteristic of this MF is the presence of a contractile apparatus. The transforming growth factor beta 1 (TGF- β 1) has an important role in the conversion of fibroblasts into MF and their maturation is due to platelet-derived growth factor. Some neoplastic epithelial cysts and tumors have a property to progress into the aggressive lesion. Stromal MF is responsible for their aggressiveness and biological behavior. So, aim of the present study is to assess and compare immunohistochemically the frequency of stromal MF in different odontogenic cysts mainly Odontogenic keratocysts (OKC), Dentigerous cysts (DCs) and Radicular cysts (RCs).

Materials and Methods: Immunohistochemical assessment of stromal MF was done on 45 cases, 15 cases of OKCs, DC, and RC, respectively. Frequency of MF was found out as a number of alpha smooth muscle actin (α -SMA) positive stromal cells in 10 high power fields. Cases of oral squamous cell carcinoma (OSCC, $n = 5$) were used as a control.

Results: OKC had the highest mean number of α -SMA positive cells per field (26.8 ± 5.193) followed by DC (14.2 ± 3.493) while RC had the lowest cells (12.5 ± 3.155). The OSCC which was used as a control showed the highest number of α -SMA positive cells per field (28.6 ± 3.050).

Conclusion: The Present study showed that the stroma is not only responsible for the support and the maintenance of the epithelial tissue but also plays a major role in the aggressive behavior of the lesion. OKC contains numerous MF in their stroma, which is similar to that found in cases of OSCC representative of its aggressive behavior and increased chances toward recurrence.

Key Words: Dentigerous cyst, myofibroblast, odontogenic keratocyst, radicular cyst, transforming growth factor beta 1

Introduction

Myofibroblasts (MF) are fibroblasts having features like a smooth muscle. Characteristic of this MF is the presence of a contractile apparatus.^{1,2} Transdifferentiation of fibroblasts into MF occurs due to transforming growth factor beta 1 (TGF- β 1) cytokine and their maturation is done by platelet-derived growth factor (PDGF).¹⁻³ Vascular smooth muscle cells possess alpha smooth muscle actin (α -SMA), which is the actin isoform expressed by MF and coordinately regulated by TGF- β 1. Synthesis of extracellular matrix (ECM) and force generation are the roles of MF due to which tissue contraction and ECM reorganization takes place during wound healing.^{1,2} At least three local events are needed to generate α -SMA positive differentiated MF: (1) Accumulation of biologically active TGF- β 1. (2) Presence of specialized ECM proteins like the ED-A splice variant of fibronectin and (3) High extracellular stress, arising from the mechanical properties of the ECM and cell remodeling activity.⁴

MF are found in normal conditions, as well as in pathological conditions.¹ Pathological conditions of oral mucosa and jaw bones which show the presence of MF are nodular fasciitis, giant cell fibroma, peripheral giant cell granuloma and cyclosporine-a induced gingival hyperplasia.¹

MF is present in the stroma reaction of epithelial tumors and may promote the progression of cancer invasion. The tumor-promoting effect of MF is based on the direct cytokine stimulation of cancer cells, maintenance of vascularity and on their capacity to produce enzymes which degrade molecules like lysyl oxidase which enhance the structural integrity of the matrix.⁵

Due to stromal MF progression of some neoplastic epithelial cysts and tumors takes place.¹ There are many epithelial-associated factors responsible for the aggressive biological behavior of the odontogenic epithelium, but non-epithelial factors also help in biological behavior of different types of odontogenic cysts and tumors.⁶ Very few studies were conducted based on this phenomenon. The coordinated activity of epithelial cells with their stroma is fundamental in controlling growth and differentiation in normal and pathological situations and is now well-accepted.⁶

The presence of MF in epithelial odontogenic cyst has not been thoroughly investigated. So, the present study was carried out to evaluate immunohistochemically the frequency of stromal MF within different odontogenic cysts mainly odontogenic keratocysts (OKCs), dentigerous cysts (DCs) and radicular cysts (RCs).

Materials and Methods

Study cases

Formalin-fixed, paraffin-embedded blocks from cases of odontogenic cysts, were retrieved from the files of the Department of Oral and Maxillofacial Pathology. These included: 15 cases of OKC-parakeratinized type from non-syndromic patients (OKC-P), DC and RC respectively. Five cases of oral squamous cell carcinoma (OSCC) served as control. Diagnoses were done on the basis of WHO criteria for odontogenic cysts by the help of Hematoxylin and Eosin stained slide.

Staining procedure

Fresh sections were cut at 3 μ thickness. Immunohistochemically staining was done using the α -SMA antibody. On positive charged slides sections were mounted. Dewaxing was done in xylene and then in ethanol, sections were dehydrated. Distilled water was used for rinsing followed by sections were placed in 3% H₂O₂ for 10 min and then again rinsed in distilled water for 15 min. After that slides were placed in citrate buffer solution, pH = 6, in a microwave at 92°C for 10 min for antigen retrieval. Then slides were allowed to cool at room temperature for 20 min then for antibody detection slides were exposed to primary α -SMA.

Evaluation of α -SMA stained sections

Randomly representative fields were selected and seen under high power. Grid, which contains 25 squares, was used for counting the cells. Ten fields were chosen for each section, immediately beneath the cystic epithelial lining grid was focused. For OSCC grid was placed immediately adjacent to tumor island, cords, and nests. Each α -SMA positive cell was counted, excluding those surrounding blood vessels and the total number of positive cells for all 10 examined fields per case was calculated. Results were presented as the mean number of α -SMA positive cells per field for each type of cysts.

Statistical analysis

Differences in the mean number of α -SMA positive cells per field among all types of lesions and comparison among the group of odontogenic cysts were analyzed using one-way ANOVA test. Statistical significance was at $P < 0.05$.

Results

The mean number was counted for α -SMA positive cells per field in all cases of OKC, DC, RC and OSCC (Table 1). Among the cysts OKC had the highest mean number of α -SMA positive cells per field (26.8 ± 5.193) followed by DC

(14.2 ± 3.493), while RC had the lowest cells (12.5 ± 3.155). The OSCC which used as a control showed the highest number of α -SMA positive cells per field (28.6 ± 3.050). Beneath and parallel to the basement membrane of these cystic lesions spindle cells showing fine α -SMA-positivity were located (Figures 1-3). While for OSCC spindle cells surrounding the tumor island, cord and nest were considered (Figure 4). Some

Table 1: Mean number of α -SMA positive cells per high power field (\pm SD) in odontogenic cysts and OSCC.

Odontogenic cysts and OSCC	MEAN α -SMA/HPF (\pm SD)
OKCs	26.8 \pm 5.193
DCs	14.2 \pm 3.493
RCs	12.5 \pm 3.155
SCC	28.6 \pm 3.050

SD: Standard deviation, OKCs: Odontogenic keratocysts, DCs: Dentigerous cysts, RCs: Radicular cysts, SCC: Squamous cell carcinoma, OSCC: Oral squamous cell carcinoma, α -SMA: Alpha smooth muscle actin, HPF: High power field

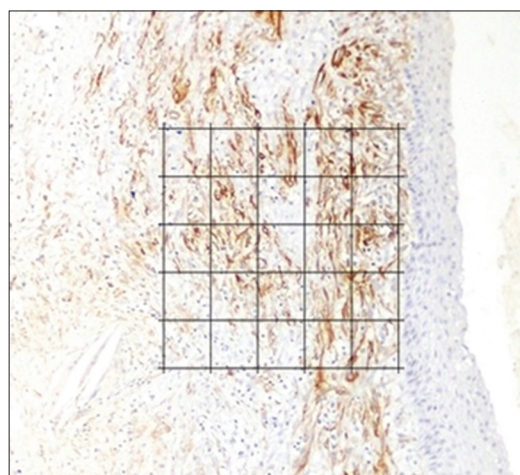


Figure 1: Photomicrograph showing myofibroblast due to alpha-smooth muscle actin expression in odontogenic keratocysts just beneath the cystic lining in the connective tissue wall (IHC stain, $\times 400$).

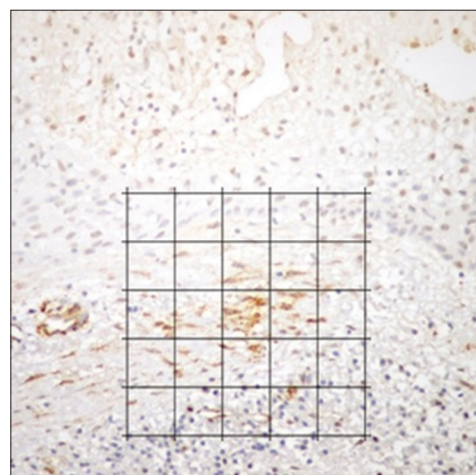


Figure 2: Photomicrograph showing myofibroblast due to alpha-smooth muscle actin expression in dentigerous cyst just beneath the cystic lining in the connective tissue wall (IHC stain, $\times 400$).

small aggregates and short bundles of similar spindle cells were found within fibrous wall especially in OKC. Positive control for the specificity of the stain was considered to those α -SMA positive cells which surrounds the blood vessel.

The statistical analysis was done by using one way ANNOVA which gave 'P' value when the comparison was done between all cysta and OSCC. For OKC 'P' value was 0.2607 and for DC and RC 'P' value was 0.0001, respectively. There was no statistically significant difference in mean number of cells of OKC and OSCC while there was statistically significant

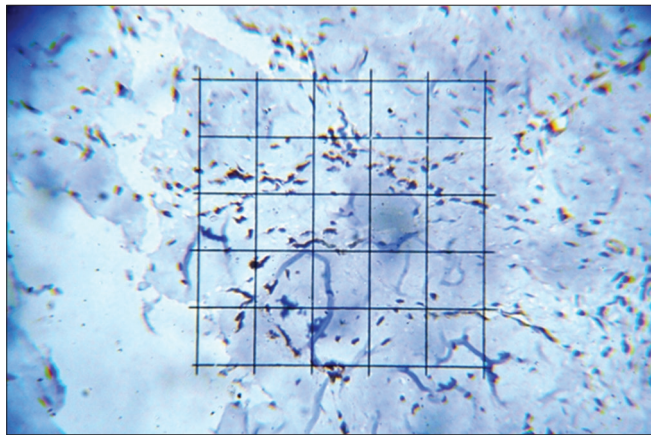


Figure 3: Photomicrograph showing myofibroblast due to alpha-smooth muscle actin expression in the radicular cyst in the connective tissue wall (IHC stain, $\times 400$).

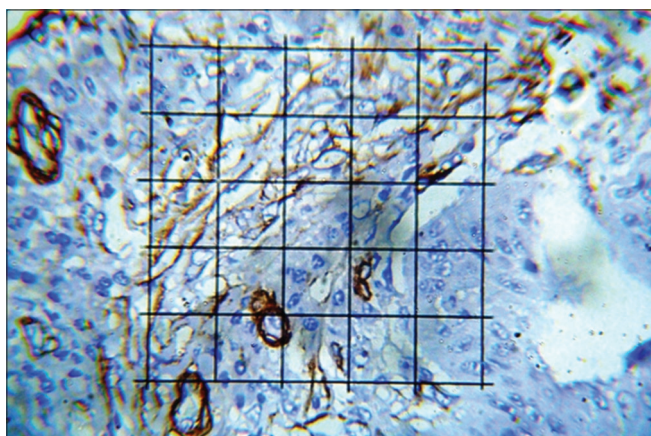


Figure 4: Photomicrograph showing myofibroblast due to alpha-smooth muscle actin expression in oral squamous cell carcinoma surrounds the tumor island within connective tissue (IHC stain, $\times 400$).

difference in mean number of cells of DC and OSCC and RC and OSCC (Table 2).

Discussion

Same sources of odontogenic epithelium share by odontogenic cysts and tumors while different degrees of aggressiveness they exhibit in their biological behavior. This discrepancy has been attributed to differences in the specific features that the epithelial component acquires during lesion development. Many epithelial-associated factors are implicated in the relative aggressive biological behavior of the odontogenic epithelium that includes increased proliferative potential as reflected by various proliferative markers.¹ OKC is an aggressive lesion with a variable biological behavior if it not adequately removed has chances of recurrence. The recurrence rate ranging from 3 to 60%.⁶ The proliferative activity of the lining epithelium of OKC has been the subject of various investigations with the expression of p53, Ki67 and proliferating cell nuclear antigen (PCNA). These markers showed highest expression in OKC than in other types of cyst and due to this high proliferation index of OKC, it should be considered as benign tumor.⁷ While DC and RC were not having that much of recurrence rate and less proliferation index, so considered as a non-aggressive lesions.^{1,8}

Many studies were conducted which demonstrates epithelial factors; only a few studies have investigated non-epithelial factors that could contribute to the variable biological behavior of the different types of odontogenic cysts. One of the study, which considered non-epithelial factor like collagen in walls of OKC, which studied histochemically by using picosirius red and stained section were examined under a polarized microscope.⁹ Results found out that collagen fibers staining in OKC was similar to that previously reported in the odontogenic neoplasm.¹⁰ This indicates that stroma of OKC not just give structural support to the cyst wall but also play a part in neoplastic behavior.⁹

In general, stromal reaction to epithelial neoplasm is marked by the appearance of MFs. Literature says, a positive link can be suggested—when more MF is present in the stroma, a more aggressive behavior of the lesion can be anticipated.^{3,11} Emergence of MF is because of PDGF and TGF- β 1 which are released by neoplastic cells at a proinvasive state. TGF- β 1 is strongly chemotactic for fibroblast even at extremely small concentration. During migration toward the cancer cells that

Table 2: Comparison among the group of odontogenic cysts were analyzed using one-way ANOVA test.

Pair	't' value	'P' value	Degree of freedom	Significant difference	Remark
OKC and OSCC	0.6673	0.2607	9	Not significant	There is no significant difference in mean number of cells of OKC and OSCC
DC and OSCC	6.944	0.0001	8	Significant	There is significant difference in mean number of cells of DC and OSCC
RC and OSCC	8.793	0.0001	10	Significant	There is significant difference in mean number of cells of RC and OSCC

OKCs: Odontogenic keratocysts, DCs: Dentigerous cysts, RCs: Radicular cysts, OSCC: Oral squamous cell carcinoma

secrete TGF- β 1, fibroblasts encounter higher concentrations of TGF- β 1, leading to their transdifferentiation into MF. This in turn, produces numerous molecules, growth and angiogenic factors, ECM components, and proteinases that together promote invasion and growth of neoplastic epithelial cells.³

In the present study, which evaluated quantitatively odontogenic cysts, has provided the findings that the stroma of these lesions harbor MF as reflected by α -SMA positive cells. Furthermore, it has been clearly shown that the mean number of MF, in the well-recognized aggressive odontogenic cyst (OKC), was high and did not differ significantly from that in OSCC. In contrast, known non-aggressive lesions (DC and RC) showed significantly lower results compared OKC.

Hence, present study showed the result that, increased expression of TGF- β 1 was found in the epithelium of cysts mainly OKC¹² and to a lesser extend in DC and RC similar to that described in the stroma of carcinomas including that of the oral cavity.^{13,14} These findings further provide an explanation to the increased frequency of MF in cases of OKC and to a lesser extend in DC and RC.

Conclusion

Hence, based on the present and previous studies, stroma is not only responsible for the support and the maintenance of the epithelial tissue but also play a major role in the aggressive behavior of the lesion. Odontogenic cyst with a high aggressive biological behavior, such as OKC, contains numerous MF in their stroma, which is similar with that found in cases of OSCC. So, OKC which is a developmental odontogenic cyst should consider as a tumor because of its aggressive behavior and named as Keratocystic odontogenic tumor.¹⁵

After surgical treatment, functional and aesthetic damage could be the complications of these extensive and aggressive odontogenic cysts. So, it is recommended to evaluate the stroma of these lesions for the frequency of MF and when abundant, there are certain anti-MF drugs^{3,16} and therapeutic agents is used which have ability reduce the extent of lesions prior to surgery.

Acknowledgment

We would like to acknowledge Dr. Ashok Patil, Professor and Head, Department of Oral and Maxillofacial Pathology, SMBT Dental College, Sangamner for his constant support during the study.

References

- Vered M, Shohat I, Buchner A, Dayan D. Myofibroblasts in stroma of odontogenic cysts and tumors can contribute to variations in the biological behavior of lesions. *Oral Oncol* 2005;41(10):1028-33.
- Tomasek JJ, Gabbiani G, Hinz B, Chaponnier C, Brown RA. Myofibroblasts and mechano-regulation of connective tissue remodelling. *Nat Rev Mol Cell Biol* 2002;3(5):349-63.
- De Wever O, Mareel M. Role of tissue stroma in cancer cell invasion. *J Pathol* 2003;200(4):429-47.
- Hinz B, Phan SH, Thannickal VJ, Galli A, Bochaton-Piallat ML, Gabbiani G. The myofibroblast: One function, multiple origins. *Am J Pathol* 2007;170(6):1807-16.
- Ganesan K, Nirmal RM, Nassar MM, Veeravarmal V, Amsaveni R, Kumar A. Evaluation of myofibroblasts in oral squamous cell carcinoma using H1 calponin: An immunohistochemical study. *J Oral Maxillofac Pathol* 2015;19(1):42-6.
- Roy S, Garg V. Evaluation of stromal myofibroblasts expression in keratocystic odontogenic tumor and orthokeratinized odontogenic cysts: A comparative study. *J Oral Maxillofac Pathol* 2013;17(2):207-11.
- Mendes RA, Carvalho JF, van der Waal I. Biological pathways involved in the aggressive behavior of the keratocystic odontogenic tumor and possible implications for molecular oriented treatment - An overview. *Oral Oncol* 2010;46(1):19-24.
- Thosaporn W, Iamaroon A, Pongsiriwet S, Ng KH. A comparative study of epithelial cell proliferation between the odontogenic keratocyst, orthokeratinized odontogenic cyst, dentigerous cyst, and ameloblastoma. *Oral Dis* 2004;10(1):22-6.
- Hirshberg A, Sherman S, Buchner A, Dayan D. Collagen fibres in the wall of odontogenic keratocysts: A study with picrosirius red and polarizing microscopy. *J Oral Pathol Med* 1999;28(9):410-2.
- Hirschberg A, Buchner A, Dayan D. The central odontogenic fibroma and the hyperplastic dental follicle: Study with Picrosirius red and polarizing microscopy. *J Oral Pathol Med* 1996;25(3):125-7.
- Mareel M, Leroy A. Clinical, cellular, and molecular aspects of cancer invasion. *Physiol Rev* 2003;83(2):337-76.
- Piattelli A, Rubini C, Fioroni M, Favero L, Strocchi R. Expression of transforming growth factor-beta 1 (TGF-beta 1) in odontogenic cysts. *Int Endod J* 2004;37(1):7-11.
- Barth PJ, Schenck zu Schweinsberg T, Ramaswamy A, Moll R. CD34+ fibrocytes, alpha-smooth muscle antigen-positive myofibroblasts, and CD117 expression in the stroma of invasive squamous cell carcinomas of the oral cavity, pharynx, and larynx. *Virchows Arch* 2004;444(3):231-4.
- Lewis MP, Lygoe KA, Nystrom ML, Anderson WP, Speight PM, Marshall JF, et al. Tumour-derived TGF-beta1 modulates myofibroblast differentiation and promotes HGF/SF-dependent invasion of squamous carcinoma cells. *Br J Cancer* 2004;90(4):822-32.
- Dineshkumar T, Priyadharsini N, Gnanaselvi UP, Sathishkumar S, Srikanth RP, Nagarathinam AE. Evaluation and comparison of vascular endothelial growth factor expression between ameloblastoma and keratocystic odontogenic tumor. *J Int Oral Health* 2015;7(1):48-52.
- De Wever O, Mareel M. Role of myofibroblasts at the invasion front. *Biol Chem* 2002;383(1):55-67.