

Stability after Cleft Osteotomy

Govind Kumar Govind¹, V Manoj Kumar², N Raakesh³, Prem Sasikumar³, B Siva⁴, Panjami Marish⁵

Contributors:

¹Professor, Department of Oral and Maxillofacial Surgery, Mahe Institute of Dental Sciences and Hospital, Chalakkara, Paloor, Mahe, Pondicherry, India; ²Professor and Head, Department of Oral and Maxillofacial Surgery, Mahe Institute of Dental Sciences and Hospital, Chalakkara, Paloor, Mahe, Pondicherry, India; ³Senior Lecturer, Department of Oral and Maxillofacial Surgery, Mahe Institute of Dental Sciences and Hospital, Chalakkara, Paloor, Mahe, Pondicherry, India; ⁴Professor and Head, Department of Oral Medicine and Radiology, Mahe Institute of Dental Sciences and Hospital, Chalakkara, Paloor, Mahe, Pondicherry, India; ⁵Senior Lecturer, Department of Orthodontics, Mahe Institute of Dental Sciences and Hospital, Chalakkara, Paloor, Mahe, Pondicherry, India.

Correspondence:

Dr. V. Manoj Kumar, Professor and HOD, Department of Oral and Maxillofacial Surgery, Mahe Institute of Dental Sciences and Hospital, Chalakkara, Mahe, Puducherry, India. E mail: drvmanoj@yahoo.com

How to cite the article:

Govind GK, Kumar VM, Raakesh N, Sasikumar P, Siva B, Marish P. Stability after cleft osteotomy. J Int Oral Health 2015;7(10):65-69.

Abstract:

Background: The primary goal in management of facial cleft is to provide normal function and esthetic appearance. Primary lip and palate repair in early childhood provide a good foundation for the normalization of the oral and para oral structures. Such early procedures have negative long-term effect on speech and psychology. The maxillary hypoplasia is the result of surgical intervention and can be rectified only by a maxillary osteotomy. The current study was undertaken to review the long-term skeletal stability and relapse patterns of consecutive series of skeletally mature patients with unilateral cleft lip and palate, maxillary hypoplasia and Class III malocclusion who had undergone Le Fort I maxillary osteotomy with advancement using miniplates for fixation.

Materials and Methods: Seven consecutive unilateral cleft palate patients with maxillary hypoplasia in one or more dimensions were studied retrospectively. All patients underwent standard Le Fort I maxillary osteotomy except one (Case VII) who had a total alveolar osteotomy. Stainless steel miniplate fixation was used for the maxilla in all cases. All the mandibular osteotomies done were stabilized with rigid fixation. The assessment of changes on the repositioned maxilla in the anteroposterior and vertical planes was made by comparing serial standardized lateral cephalograms taken pre-operatively, immediate post-operatively, 6 months and 1-year. Last two cases (Case VI and VII) have only 6 months follow-up.

Results: In 5 out of 7 cases, the maxilla was surgically moved downward and advanced. Two cases required surgical impaction and advancement. The mean horizontal movement was 5.93 mm and the vertical movement was 2.80 mm. The calculated total relapse ranged from 0.40 to 3.41 mm in the horizontal plane

and 0.35-2.22 mm in the vertical plane respectively. Six out of 7 patients receiving orthodontic therapy had their upper incisor to SN angulations increased since the early post-operative period, suggesting that orthodontic treatment compensated for the skeletal relapse by proclining the anterior teeth.

Conclusion: Our study concludes that there is no direct correlation between the amount of skeletal relapse and the amount of horizontal advancement or vertical change. The problem of relapse in unilateral cleft lip and palate patients may be reduced; however cannot be completely eliminated.

Key Words: Cleft lip, cleft palate, cleft osteotomy, maxillary hypoplasia, total relapse

Introduction

Facial clefting presents challenges to the various constituents of the team whose ultimate goal is to provide normal function and esthetic appearance. Primary lip and palate repairs carried out in infancy/early childhood provides a good foundation for the normalization of the oral and para oral structures. Unfortunately, one long-term effect of the early surgical procedure is maxillary growth restriction that produces secondary deformities of the jaws and occlusion producing a negative impact on speech and psychology. The observed maxillary hypoplasia is the result of surgical intervention and not attributable to the clefting. This can be rectified only by a maxillary osteotomy.

Correction in most cases entails not only maxillary advancement but also inferior repositioning and arch expansion. With well-coordinated orthodontic decompensation and alignment of the segments pre-surgically, a single stage maxillary osteotomy can be performed.

The long-term stability of any osteotomy is an essential prerequisite for a successful outcome. Maxillary cleft osteotomies fixed with wire osteosynthesis were subject to significant post-surgical relapse. Attempts to reduce relapse by a longer period of intermaxillary fixation, the use of wire suspension, bone pins, craniomaxillary fixation, or bone plates met with variable success. Today, the use of miniplate fixation in maxillofacial surgery is routine.

Stoelinga *et al.*¹ studied the relapse of this form of osteotomy fixed with wire or miniplates and showed good stability in the transverse and anteroposterior planes in the selected sample of cleft patients. Posnick and Dagsy² studied skeletal stability after Le Fort I maxillary advancement in 30 patients with unilateral cleft lip and palate. They found

no statistically significant differences in outcome between patients who had maxillary surgery alone and those who had operations in both jaws, nor did the outcome vary significantly with the type of autogenous bone grafts used or the segmentalization of the Le Fort I osteotomy. In spite of improvements in surgical technique and postsurgical fixation, there is a much higher tendency to relapse in cleft patients when compared with non-cleft patients with maxillary hypoplasia.³

Though the use of mini plates in preventing surgical relapse is well established, most studies on relapse rate after Le Fort I osteotomy in cleft patients have the disadvantage of including mixed cleft type.⁴ (i.e., unilateral cleft lip and palate and bilateral cleft lip and palate). In addition, an extensive review of the English language literature failed to disclose comparable studies from the Asian subcontinent.

The current study was undertaken to review the long-term skeletal stability and relapse patterns of a consecutive series of skeletally mature patients with unilateral cleft lip and palate and maxillary hypoplasia and Class III malocclusion who had undergone Le Fort I maxillary osteotomy with advancement fixed with miniplates.

Materials and Methods

Materials

This is a retrospective study of seven consecutive unilateral cleft palate patients with maxillary hypoplasia in one or more dimensions. All patients underwent standard Le Fort I maxillary osteotomy except one (Case VII) who had a total alveolar osteotomy. There were 4 females and 3 males with a mean age of 20 years. Five patients had inferior repositioning and 2 patients had superior repositioning of the maxilla. All 5 patients had an interpositional corticocancellous bone graft. In all the cases, the graft was taken from the iliac crest except one (Case VI) which was taken from the mandibular symphysis.

Stainless steel mini-plate fixation was used for the maxilla in all cases. Four miniplates were used for each maxilla in a standard manner, one at each zygomatic buttress and pyriform aperture region. Simultaneous mandibular surgery was performed in four cases. All the mandibular osteotomies were stabilized with rigid fixation.

Methods

The skeletal stability after surgery was evaluated from cephalometric radiographs. The assessment of changes in the repositioned maxilla in the anteroposterior and vertical planes was made by comparing serial standardized lateral cephalograms taken pre-operatively, immediate post-operatively, 6 months, and 1-year. Last two cases (Case VI and VII) have only 6 months follow-up.

Radiographs

Lateral cephalograms taken pre-operatively, immediate post-operatively, 6 months, and 1-year lateral cephalograms were obtained with the subject's head positioned in natural head position looking into their eyes on a mirror with relaxed lips, and the patient in "centric occlusion." The relaxed lip position has been suggested as the best posture for cephalometric evaluation. The cephalostat used was Satelec. The distance between the subject and the X-ray tube was fixed at 150 cm and the median plane to film distance was 15 cm and thus the constant enlargement was 10%. All the X-rays were taken on a Kodak T Matte-E in a 8 × 10-inch cassette. The exposure was made at 1.5 s, 32 RNA and 80 Kvp. All the films were manually developed under controlled conditions. Each pre-surgical and post-surgical cephalogram was taken on the same cephalostat to eliminate the need for correction of radiographic magnification. Tracing of all cephalograms used in this study was made on matt acetate film of 50 μ thickness and were traced by the same operator, using a 0.5 mm lead pencil, respectively. All four radiographs of a patient were traced at the same sitting to minimize tracing errors.

Landmarks and measurements employed in the cephalometric analysis:

- Sella turcica (S)
- Nasion (N)
- Point A (A)
- Upper incisal edge (Sie)
- Sie to SN angulation.

A line was drawn from Sella to nasion (SN Line) and the horizontal plane was taken at 7° from SN (Figure 1).

Results

In 5 out of 7 cases, the maxilla was surgically moved downward and advanced. Two cases required surgical impaction and

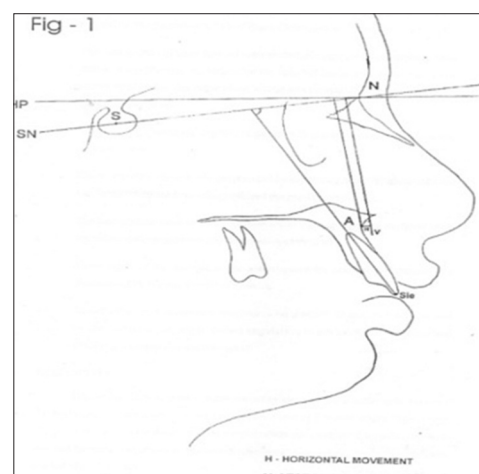


Figure 1: Landmarks and measurements employed in the cephalometric analysis: Sella turcica (S), Nasion (N), Point A (A), Upper incisal edge (Sie), Sie to SN angulation.

advancement. The mean horizontal movement (Table 1) was 5.93 mm (range 1.66-14.54 mm) and the vertical movement (Table 2) was 2.80 mm (range 0.82-6.94 mm). The calculated total relapse ranged from 0.40 to 3.41 mm in the horizontal plane and 0.35-2.22 mm in the vertical plane, respectively.

The amount of relapse for each individual case was variable. For cases with surgical movement in the anteroposterior plane of 5 mm or less the percentage relapse ranged from 0.26 to 2.38 mm in 6 months and 0.40-1.55 mm in 1-year, respectively. The top range was high due to the small amount of movement, but the maximum absolute relapse was only 2.38 mm. When the surgical movement in the anteroposterior plane was more than 5 mm, the relapse ranged from 2.70 to 2.98 mm in 6 months follow-up, and 3.41-4.51 mm at 1-year, respectively.

When the vertical movement was <2 mm the relapse ranged from 0.20 to 2.14 mm in 6 months follow-up and 0.35-2.14 mm in 1-year, respectively. The absolute amount was 2.14 mm. When the movement was more than 2 mm the relapse ranged from 1.55 to 1.96 mm in 6 months follow-up and 1.90-2.22 mm in 1-year follow-up, respectively.

The continuous surgical relapse at point 'A' in the horizontal and vertical planes was analyzed over a 1-year period. Most of the relapse in the horizontal plane occurred in the first 6 months and slowed down gradually till 1-year. In the vertical plane, the post-surgical relapse was most marked in the first 6 months and slowed down till 1-year.

"Six out of 7 patients receiving orthodontic therapy had their upper incisor to SN angulations increased (Table 3) since the early post-operative period, suggesting that orthodontic treatment compensated for the skeletal relapse by proclining the anterior teeth."

Discussion

Despite successful, well-timed surgery and adequate orthodontic treatment, and maxillary hypoplasia appears to be unavoidable in some patients with cleft lip and palate.^{5,6} In these cases, Le Fort I maxillary advancement osteotomy is usually performed when the patients reach adolescence. Treatment planning and operation are more complex in cleft patients because the amount of advancement tends to be larger and the degree of malocclusion is worse.^{7,8} In addition, Le Fort I osteotomy in cleft patients is more difficult to perform and the relapse rate is larger.³

Most studies on the stability of maxillary osteotomies in cleft lip and palate patients were carried out on a mixture of different types of fixation making their analysis of the benefits of an individual method difficult. Fixation with wire osteosynthesis alone in cleft osteotomies is associated with considerable relapse which could not be significantly reduced by supplementary wire suspension and bone pins. A stronger

Cases	Total advancement (mm)	Relapse in 6 months (mm)	Relapse in 1-year (mm)
Case I	3.22	1.24	1.55
Case II	7.92	2.98	3.41
Case III	5.08	1.20	4.51
Case IV	3.42	0.26	0.40
Case V	5.68	2.02	3.26
Case VI	1.66	2.38	
Case VII	14.54	2.70	-
Mean	5.93	1.83	2.63
Rate of relapse (%)		30.86	44.35

Cases	Total vertical repositioning (mm)	Relapse in 6 months (mm)	Relapse in 1-year (mm)
Case I	5.67	1.96	2.22
Case II	0.97	1.53	2.14
Case III	6.94	1.55	1.90
Case IV	1.69	0.20	0.35
Case V	1.72	0.46	0.68
Case VI	0.82	2.14	-
Case VII	1.80	1.74	-
Mean	2.80	1.37	1.46
Rate of relapse (%)		0.4892	0.521

Cases	Immediate post-operative	6 months	1-year
Case I	77°	74°	72°
Case II	75°	66°	61°
Case III	96°	94°	90°
Case IV	84°	80°	65°
Case V	75°	66°	59°
Case VI	63°	59°	-
Case VII	74°	72°	-

SN: Sella-nasion

form of fixation was therefore suggested by Garrison *et al.*⁹ Earlier studies supporting the use of miniplate fixation has shown significantly less relapse when compared with that of wire fixation. The superiority of mini plates in reducing the relapse in both the horizontal and vertical planes was reported by many.¹⁰ This study comprises a uniform group of unilateral cleft lip and palate patients, all requiring maxillary advancement and most with inferior repositioning except two cases where we did superior repositioning using a standardized method of mini plate fixation. We evaluated our patients for 1-year with serial cephalograms.

Cephalometric analysis in cleft patients is difficult due to the problem of landmark identification particularly 'A' point. Point 'A' is the deepest point on the contour of the alveolar projection between the spinal point and the prosthion. The projection of the cheeks in living persons frequently obscures that landmark in a cephalogram. In examining several craniums, it appeared

that the point 'A' is not an ideal reference point; according to the findings of second research workshop in roentgenographic cephalometry. However, Cheung *et al.*¹¹ demonstrated that the point 'A' in the maxilla is a stable landmark. Following this study point 'A' is now considered a standard reference point.

Multiple factors are considered to be related to relapse after maxillary advancement in cleft patients. Surgical movement and relapse are assessed individually in the horizontal and vertical direction. In our series, two of the patients underwent superior repositioning and the rest had inferior repositioning. The mean horizontal relapse in 6 months and 1-year was 30.8% and 44.35% of the mean advancement, which is much higher than that reported by other studies.¹²⁻¹⁴ Some authors have reported a significant correlation between the advancement and the relapse, whereas others report no correlation.⁸ In our study, we found a significant correlation between the extent of surgical advancement and the extent of relapse. Scarring in the palate and retro maxillary region seems to be one of the factors causing relapse, so it seems natural to assess any association between advancement and relapse. To avoid this problem we have done 1 total alveolar osteotomy by tunneling via vertical incisions on the buccal aspect.

Sufficient mobilization of the maxilla during surgeries seems to be important to prevent relapse.¹⁵ Resistance does not always increase in proportion to surgical advancement. The maxillary segment can usually be moved forward to some extent without any resistance. We believe that the maxilla should be advanced until there is a slight resistance felt by the operator.

There was no difference in the rate of relapse among patients undergoing maxillary surgery alone and those undergoing two-jaw surgery. In our series, two-jaw surgery was indicated in three patients. We did not find any difference in the rate of relapse between single jaw surgery and double jaw surgery.

Vertical abnormalities in maxillary position are frequently seen in cleft patients. Vertical maxillary deficiency is more common, but vertical maxillary excess also occurs. There was a correlation between the amount of vertical displacement and relapse, and there was a significant difference between inferior repositioning and maxillary intrusion. Inferior repositioning is more unstable procedure compared with the maxillary intrusion.¹⁶ In our series, five patients had inferior repositioning. Corticocancellous blocks were placed in the osteotomy gaps. All patients had grafts taken from the iliac region except one (Case VI) which was taken from the anterior mandible-genial region. The mean vertical repositioning was 2.8 mm while the mean relapse in 6 months and 1-year was 1.37 mm and 1.46 mm, respectively. The 6 months interval showed a relapse rate of 48.92% while that of a 1-year follow-up was 52.1%. The degree of vertical relapse has been reported to be variable.¹⁶ The reason for these differences is unknown.

Summary and Conclusion

This retrospective study was conducted in seven consecutive unilateral cleft lip and palate patients with maxillary hypoplasia to evaluate the stability after maxillary osteotomy. All patients underwent standard Le Fort I maxillary osteotomy except one who had a total alveolar osteotomy. Five patients had inferior repositioning and two patients had superior repositioning of the maxilla. All five patients had interpositional corticocancellous bone graft. In all the cases, the graft was taken from the iliac crest except one, which was taken from the mandibular symphysis. Stainless steel miniplate fixation was used for the maxilla in all cases.

The skeletal stability after surgery was evaluated from cephalometric radiographs. The assessment of changes on the repositioned maxilla in the anteroposterior and vertical planes was made by comparing serial standardized lateral cephalograms taken pre-operatively, immediate post-operatively, 6 months, and 1-year.

Important observations came to light in the course of this study:

1. The mean horizontal movement was 5.93 mm and the calculated relapse was 30.86% in 6 months and 44.35% in 1-year, respectively
2. The mean vertical movement was 2.80 mm and the calculated relapse was 48.92% in 6 months and 52.1% in 1-year, respectively
3. In patients receiving orthodontic therapy, their upper incisor to SN angulation increased since the early post-operative period, suggesting that orthodontic treatment compensated for the skeletal relapse by proclining the anterior teeth.

In conclusion, we confirm the findings of other investigators that no direct correlation could be found between the amount of horizontal advancement or vertical change and the amount of skeletal relapse. This suggests that the cause of relapse is multifactorial and cannot be explained by cleft palate scar tissue alone. Although our surgical technique and all the accommodations have been useful, they have not completely eliminated the problem of relapse in a series of unilateral cleft lip and palate patients.

References

1. Stoelinga PJ, Leenen RJ, Blijdorp PA, Schoenaers JH. The prevention of relapse after maxillary osteotomies in cleft palate patients. *J CranioMaxillofac Surg* 1987;15(6):326-31.
2. Posnick JC, Dagys AP. Skeletal stability and relapse patterns after Le Fort I maxillary osteotomy fixed with miniplates: The unilateral cleft lip and palate deformity. *Plast Reconstr Surg* 1994;94(7):924-32.
3. Hirano A, Suzuki H. Factors related to relapse after Le Fort I maxillary advancement osteotomy in patients with cleft lip and palate. *Cleft Palate Craniofac J* 2001;38(1):1-10.

4. Posnick JC. Cleft jaw deformities and their management. In: *Cleft Lip and Palate*, Heidelberg: Springer Berlin; 2013. p. 557-99.
5. Ross RB. Treatment variables affecting facial growth in complete unilateral cleft lip and palate. *Cleft Palate J* 1987;24(1):5-77.
6. Oberoi S, Hoffman WY, Chigurupati R, Vargervik K. Frequency of surgical correction for maxillary hypoplasia in cleft lip and palate. *J Craniofac Surg* 2012;23(6):1665-7.
7. Hochban W, Ganß C, Austermann KH. Long-term results after maxillary advancement in patients with clefts. *Cleft Palate Craniofac J* 1993;30(2):237-43.
8. Saltaji H, Major MP, Altalibi M, Youssef M, Flores-Mir C. Long-term skeletal stability after maxillary advancement with distraction osteogenesis in cleft lip and palate patients: A systematic review. *Angle Orthod* 2012;82(6):1115-22.
9. Garrison BT, Lapp TH, Bussard DA. The stability of Le Fort I maxillary osteotomies in patients with simultaneous alveolar cleft bone grafts. *J Oral Maxillofac Surg* 1987;45(9):761-5.
10. Cheung LK, Chua HD. A meta-analysis of cleft maxillary osteotomy and distraction osteogenesis. *Int J Oral Maxillofac Surg* 2006;35(1):14-24.
11. Cheung LK, Samman N, Hui E, Tideman H. The 3-dimensional stability of maxillary osteotomies in cleft palate patients with residual alveolar clefts. *Br J Oral Maxillofac Surg* 1994;32(1):6-12.
12. Willmar K. On Le Fort I osteotomy; a follow-up study of 106 operated patients with maxillo-facial deformity. *Scand J Plast Reconstr Surg* 1974;12:1-68.
13. Poole MD, Robinson PP, Nunn ME. Maxillary advancement in cleft palate patients. A modification of the Le Fort I osteotomy and preliminary results. *J Maxillofac Surg* 1986;14:123-7.
14. Viwattanatipa N, Puntien T, Ammarin Thakkinstian. Systematic review and meta-analysis of maxillary change among 3 surgical techniques in cleft patients. *Orthod Waves* 2013;72(2):63-76.
15. Araujo A, Schendel SA, Wolford LM, Epker BN. Total maxillary advancement with and without bone grafting. *J Oral Surg* 1978;36(11):849-58.
16. Wolford LM, Hilliard FW. The surgical-orthodontic correction of vertical dentofacial deformities. *J Oral Surg* 1981;39(11):883-97