

Bioresorbable Plates and Screws in Maxillomandibular Fractures

Ramya Rajanna¹, Jayaprasad N Shetty², Ramdas Balakrishna³, Abhinandan Patel⁴, Krishna Mohan Sringeri⁵, Girish Gireddy⁶

Contributors:

¹Senior Lecturer, Department of Oral & Maxillofacial Surgery, Sri Siddhartha Dental College and Hospital, Agalkote, Tumkur, Karnataka, India; ²Professor and Head, Department of Oral & Maxillofacial Surgery, The Oxford Dental College, Hospital and Research Center, Bengaluru, Karnataka, India; ³Professor and Head, Department of Oral and Maxillofacial Surgery, KLE Society's Institute of Dental Sciences, Yeshwanthpur, Bengaluru, Karnataka, India; ⁴Oral & Maxillofacial Surgeon, Department of Oral & Maxillofacial Surgery, Sanjay Gandhi Trauma & Accident Hospital, Bengaluru, Karnataka, India; ⁵Anaesthetist, Department of Oral & Maxillofacial Surgery, The Oxford Dental College, Hospital and Research Center, Bengaluru, Karnataka, India; ⁶Head and Oral & Maxillofacial Surgeon, Department of Oral & Maxillofacial Surgery, Government Dental College, Bengaluru, Karnataka, India.

Correspondence:

Dr. Rajanna R. Department of Oral & Maxillofacial Surgery, Sri Siddhartha Dental College and Hospital, B.H Road, Agalkote, Tumkur - 572 107, Karnataka, India. Phone: +91-9739653117. Email: ramya_rajanna@yahoo.com

How to cite the article:

Rajanna R, Shetty JN, Balakrishna R, Patel A, Sringeri KM, Gireddy G. Bioresorbable Plates and Screws in Maxillomandibular Fractures. J Int Oral Health 2015;7(12):78-85.

Abstract:

Background: In treating facial fractures, stable fixation, prevention of infection and uncomplicated healing are the ultimate goals. In this study bioresorbable polylactic and polyglycolic acid (PLA and PGA) copolymer plates and screws (bioresorbable) were used to treat maxillomandibular fractures as an alternative to metal devices. The role of these plates in the internal fixation of maxillomandibular fractures has been the objective of the study.

Materials and Methods: About 10 healthy patients in the age group of 10-40 years with maxillomandibular fractures less than 21 days old with no systemic predisposing conditions, requiring open reduction and internal fixation attending the outpatient Department of Oral and Maxillofacial Surgery of the Oxford Dental College and Hospital were selected for the study. Patients selected for the study were treated with self-reinforced polylactic acid (82%) and self-reinforced polyglycolic acid (18%) copolymer plates and screws. Patients were followed up at the interval of 3 weeks, 6 weeks, 3 months, and 6 months post-operatively. Periodic clinical examination to evaluate the parameters namely swelling, mucosal discoloration, pain, occlusal disturbance, and fracture stability. Post-operative orthopantomogram was taken in all the cases to evaluate radiologically the fracture healing and screw-hole ossification.

Results: All fractures were found to be adequately fixed clinically. None of them had a delayed union or a nonunion and normal occlusion was achieved in all cases, which in principle proves the reliability of the method. Jaw opening was adequate in all cases, and

no post-operative infections were seen in any of the cases at the end of 6 months follow-up.

Conclusion: The study demonstrated self-reinforced PLA and PGA copolymer plates and screws (bioresorbable) can be successfully used in internal fixation of maxillofacial fractures. The findings of this study indicate bioresorbable plates and screws to be a very promising material which could save considerable cost and eliminate the need for the second operation. In the present study, it is seen that bioresorbable plates and screws are effective in the treatment of maxillomandibular fractures with least complication rates.

Key Words: Bioresorbable, orthopantomogram, self-reinforced polyglycolic acid, self-reinforced polylactic acid copolymer plates and screws

Introduction

Maxillofacial injuries are a frequent occurrence in individuals who suffer trauma, such as motor vehicle accidents, assaults, and falls.

Fracture with bone displacement may cause functional and cosmetic problems, and their management should include reduction and fixation to restore normal function and appearance.

Internal fixation devices have long been used to reduce and stabilize maxillofacial fractures. These have included metal wires, metal plates. The concept of monocortical miniplate fixation developed in 1970s gained popularity as a reliable internal fixation method of achieving osteosynthesis which allows simultaneous passive or even functional loading of the fracture or osteotomized bone segments if applied properly.¹

Internal fixation was achieved by placing stainless steel plates and screws, titanium plates and screws which were used routinely.

Though these have fulfilled most qualities of the biomaterial requisites, they have a lot of inherent disadvantages. Their stiffness can cause stress shielding effect on the bone leading to osteoporosis under the plate. It could interfere with the growth of the region; migrate intracranially if placed on the calvarial bone necessitating its removal.¹

In addition, metal plate systems may be displaced or cause artifacts on radiographs, being influenced by the magnetic field produced during magnetic resonance imaging.²

Further, it presents material related disadvantages such as corrosion and spread of metal into the tissues,³ thermal sensitivity,⁴ and interference with computer tomography, hypersensitivity and carcinogenic potential.⁵

In view, of the potential shortcomings of metal fixation devices an attempt was made to introduce an alternative material which compensates all the advantages of the metallic fixation, hence, bioresorbable plates, and screws were introduced.

Bioresorbable plates and screws are considered as an advance for the internal fixation technique because it keeps their structural integrity during bone callus formation period. Their main advantages are that they are biologically inert, presents no thermal conductivity.

They provide adequate strength during the consolidation of the osteotomy or fracture in the facial skeleton, and they degrade by time, eliminates the need for the second operation for their removal. Bioresorbable devices have not been found to have apparent effect on cranial growth.⁶

Their modulus of elasticity stimulates bone; stress shielding effect is not a feature. Due to slow resorption they transfer stresses slowly to bone preventing osteoporosis.¹ Decreases the radiographic reflex, allowing the examination using computer tomography and magnetic resonance.⁷

As a tissue equivalent, bioresorbable devices do not interfere with post-operative radiotherapy.⁶

Clinical and radiological studies demonstrated their safety and efficiency and as a viable alternative to traditional metal devices in selected patients.⁸

In this present prospective study, efforts have been made to evaluate clinically and radiologically the role of bioresorbable plates and screws in the management of maxillomandibular fracture as an alternative to the traditional metal device.

Materials and Methods

The 10 healthy patients in the age group of 10-40 years with maxillomandibular fractures less than 21 days old with no systemic predisposing conditions, requiring open reduction and internal fixation attending the outpatient Department of Oral and Maxillofacial Surgery of the Oxford Dental College and Hospital were selected for the study. Patients were explained about the protocol of the treatment (Figures 1 and 4).

Patients selected for the study were treated with self-reinforced polylactic acid (82%) and self-reinforced polyglycolic acid (18%) copolymer plates and screws (bioresorbable plates and screws).

Under general anesthesia the surgical site was exposed with either an intra-oral or an extra oral incision depending on the fracture site.

After adequate exposure of fracture fragments, intermaxillary fixation (IMF) was done to bring the fracture fragments into their anatomical form. Self-reinforced copolymer plates (polylactic acid/polyglycolic acid [PLA/PGA]) of 2.5 mm were adopted onto the fracture site by making use of hot water bath. Drill holes were made, to place screws of 6, 8, 10, and 12 mm depending on the fracture site and the fracture was fixed in accordance with CHAMPY'S principle. In the case of symphysis and parasymphysis fracture, two miniplates were used. In the case of angle fracture, a single plate was used at the superior border of the mandible. In the body region, a single plate above the mandibular canal was used to fix the fracture taking care not to damage the roots of the teeth.

IMF was removed leaving arch bars in place at the end of the procedure. Wound closure was done in layers using 3-0 vicryl sutures. Dressing was given for the extra oral wound.

All patients received 1 g intravenous amoxicillin preoperatively and post-operative antibiotics and analgesics for 5 days and were instructed to maintain a soft diet for 6 weeks. All patients were advised to maintain oral hygiene using 0.2% chlorhexidine mouthwash.

Patients were followed up at the interval of 3 weeks, 6 weeks, 3 months, and 6 months post-operatively for periodic clinical examination to evaluate healing of the fracture, occlusion stability and also radiographic examination was conducted to assess ossification of screw-hole and fracture union.

Results

This prospective study conducted on 10 patients visiting Department of Oral and Maxillofacial Surgery, Oxford Dental College and Research Institute, Bengaluru, Karnataka, India with the diagnosis of maxillomandibular fractures to evaluate the role of bioresorbable self-reinforced PLA and PGA copolymer plates and screws in internal fixation of fractures. All the patients were treated on in-patient basis.

The age of the patients participating in this study ranged from 13 to 36 years. Most of them were male patients, majority of patients had etiology of motor vehicle accident (6), followed by assault (1) and work related or self-fall (3) (Graph 1).

Fracture distribution consisted of parasymphysis (6), body (2), 1 angle fractures and left infraorbital rim fracture (1) with a total of 13 fracture sites in the 10 selected cases.

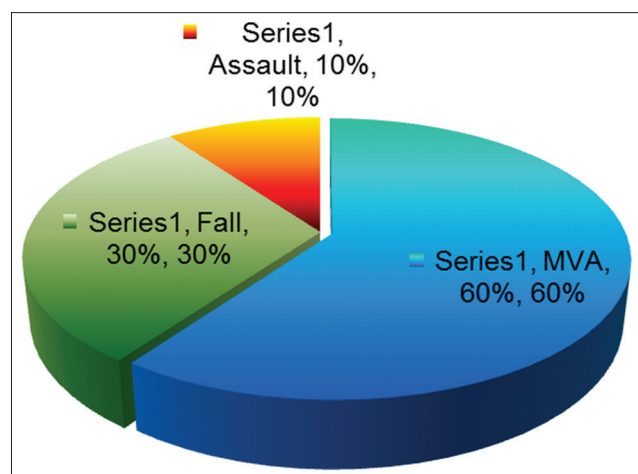
The fractures were treated ranging from 1 to 20 days from the time of injury. Adequacy of fracture fixation with bioresorbable plates and screw system was checked immediately after fixation and at the end of 3 weeks, 6 weeks, 3 months, and 6 months post-operatively by, clinical evaluation with the parameters like swelling, mucosal discoloration, pain, occlusal disturbance and fracture stability.

Post-operative orthopantomogram was taken in all the cases to evaluate radiologically the fracture healing and screw-hole ossification (Master Chart).

All fractures were found to be adequately fixed both clinically and radiographically. None of the patients had complications of non-union or mal-union. One patient reported with mild sensitivity of lower left first premolar due to periapical infection at the end of 6 months. Another patient had mild intropian seen after 6 months of follow-up. None patients had any occlusal discrepancies except one patient who had an anterior open bite throughout the follow-up period attributed to bicondylar fractures. Jaw opening was adequate in all cases, and no post-operative infections were seen at the end of 6 months of follow-up.

Case 1

Name: Vijaykumar
Age: 24 years



Graph 1: Distribution of patients according to aetiology.

Sex: Male

Case history: Fracture of left parasymphysis with right subcondylar fracture

Post-operative follow-up after treatment with bioresorbable plates and screws are shown in Table 1.

Case 2

Name: ED Sreenivas

Age: 31 years

Sex: Male

Case history: Fracture of left body of mandible

Post-operative follow-up after treatment with bioresorbable plates and screws are shown in Table 2.

Case 3

Name: Raju

Year: 19 years

Sex: Male

Case history: Fracture of right infraorbital rim

Post-operative follow-up after treatment with bioresorbable plates and screws are shown in Table 3.

Table 1: Post-operative follow-up (Case 1).				
Evaluation	3 weeks	6 weeks	3 months	6 months
Clinical evaluation				
Swelling	Moderate	Moderate	Absent	Absent
Mucosal discoloration	Normal	Normal	Not present	Absent
Pain	Moderate	Mild	Nil	Absent
Occlusion relation	Class 1 molar	Class 1 molar	Class 1 molar	Class 1 molar
Fracture stability	Good	Good	Good	good
Radiological evaluation				
Fracture healing	Satisfactory	Satisfactory	Satisfactory	Satisfactory
Screw hole ossification	Absent	Absent	Mild	Moderate

Master chart.									
Age/sex	Name	Fracture site	Material used	Post-operative weeks, months	Occlusion	Infection	Mobility of fragment	Fracture reduction	Jaw opening
24	Vijaykumar	Left parasymphysis	PLA/PGA plates and screw	3 weeks, 6 weeks, 3 months, 6 months	Normal	Absent	Absent	Satisfactory	Adequate
31	Sreenivas	Left body	PLA/PGA plates and screw	3 weeks, 6 weeks, 3 months, 6 months	Normal	Absent	Absent	Satisfactory	Adequate
19	Raju	Right infraorbital rim	PLA/PGA plates and screw	3 weeks, 6 weeks, 3 months, 6 months	Normal	Absent	Absent	Satisfactory	Adequate
23	Manju	Left body	PLA/PGA plates and screw	3 weeks, 6 weeks, 3 months, 6 months	Normal	Absent	Absent	Satisfactory	Adequate
14	Thygaraj	Right parasymphysis	PLA/PGA plates and screw	3 weeks, 6 weeks, 3 months, 6 months	Normal	Absent	Absent	Satisfactory	Adequate
36	Mohan K	Right angle	PLA/PGA plates and screw	3 weeks, 6 weeks, 3 months, 6 months	Normal	Absent	Absent	Satisfactory	Adequate
34	Murthy	Left parasymphysis	PLA/PGA plates and screw	3 weeks, 6 weeks, 3 months, 6 months	Normal	Absent	Absent	Satisfactory	Adequate
33	Rahim	Left parasymphysis	PLA/PGA plates and screw	3 weeks, 6 weeks, 3 months, 6 months	Normal	Absent	Absent	Satisfactory	Adequate
21	Imran	Right para with bilatrl condyle	PLA/PGA plates and screw	3 weeks, 6 weeks, 3 months, 6 months	Normal	Absent	Absent	Satisfactory	Adequate
18	Abdul	Left parasymphysis	PLA/PGA plates and screw	3 weeks, 6 weeks, 3 months, 6 months	Normal	Absent	Absent	Satisfactory	Adequate

PLA: Polylactic acid, PGA: Polyglycolic acid

Case 4

Name: Manju

Age: 23 years

Sex: Female

Case history: Fracture of left body of mandible

Post-operative follow-up after treatment with bioresorbable plates and screws are shown in Table 4.

Case 5

Name: Thygaraj

Age: 14 years

Sex: Male

Case history: Fracture of right parasymphysis of mandible

Table 2: Post-operative follow-up (Case 2).				
Evaluation	3 weeks	6 weeks	3 months	6 months
Clinical evaluation				
Swelling	Moderate	Moderate	Absent	Absent
Mucosal discoloration	Normal	Normal	Not present	Absent
Pain	Moderate	Moderate	Mild	Mild
Occlusion relation	Class 1 molar	Class 1 molar	Class 1 molar	Class 1 molar
Fracture stability	Good	Good	Good	Good
Radiological evaluation				
Fracture healing	Satisfactory	Satisfactory	Satisfactory	Satisfactory
Screw hole ossification	Absent	Absent	Mild	Moderate

Table 3: Post-operative follow-up (Case 3).				
Evaluation	3 weeks	6 weeks	3 months	6 months
Clinical evaluation				
Swelling	Moderate	Moderate	Absent	Absent
Mucosal discoloration	Normal	Normal	Not present	Absent
Pain	Moderate	Mild	Nil	Absent
Occlusion relation	Class 1 molar	Class 1 molar	Class 1 molar	Class 1 molar
Fracture stability	Good	Good	Good	Good
Radiological evaluation				
Fracture healing	Satisfactory	Satisfactory	Satisfactory	Satisfactory
Screw hole ossification	Absent	Absent	Mild	Moderate

Table 4: Post-operative follow-up (Case 4).				
Evaluation	3 weeks	6 weeks	3 months	6 months
Clinical evaluation				
Swelling	Moderate	Moderate	Mild	Absent
Mucosal discoloration	Normal	Normal	Not present	Absent
Pain	Moderate	Absent	Nil	Absent
Occlusion relation	Class 1 molar	Class 1 molar	Class 1 molar	Class 1 molar
Fracture stability	Good	Good	Good	Good
Radiological evaluation				
Fracture healing	Satisfactory	Satisfactory	Satisfactory	Satisfactory
Screw hole ossification	Absent	Absent	Mild	Moderate

Post-operative follow-up after treatment with bioresorbable plates and screws are shown Table 5.

Case 6

Name: Mohan Kumar

Age: 36 years

Sex: Male

Case history: Fracture of right angle of mandible

Post-operative follow-up after treatment with bioresorbable plates and screws are shown in Table 6.

Case 7

Name: Murthy

Age: 34 years

Sex: Male

Case history: Fracture of left para symphysis region of mandible

Post-operative follow-up after treatment with bioresorbable plates and screws are shown in Table 7.

Case 8

Name: Rahim

Age: 33 years

Sex: Male

Case history: Fracture of left parasymphysis of mandible

Post-operative follow-up after treatment with bioresorbable plates and screws are shown in Table 8.

Table 5: Post-operative follow-up (Case 5).				
Evaluation	3 weeks	6 weeks	3 months	6 months
Clinical evaluation				
Swelling	Moderate	Moderate	Absent	Absent
Mucosal discoloration	Normal	Normal	Not present	Absent
Pain	Moderate	Absent	Nil	Absent
Occlusion relation	Class 1 molar	Class 1 molar	Class 1 molar	Class 1 molar
Fracture stability	Good	Good	Good	Good
Radiological evaluation				
Fracture healing	Satisfactory	Satisfactory	Satisfactory	Satisfactory
Screw hole ossification	Absent	Absent	Mild	Moderate

Table 6: Post-operative follow-up (Case 6).				
Evaluation	3 weeks	6 weeks	3 months	6 months
Clinical evaluation				
Swelling	Moderate	Moderate	Absent	Absent
Mucosal discoloration	Normal	Normal	Not present	Absent
Pain	Moderate	Absent	Nil	Absent
Occlusion relation	Class 1 molar	Class 1 molar	Class 1 molar	Class 1 molar
Fracture stability	Good	Good	Good	Good
Radiological evaluation				
Fracture healing	Satisfactory	Satisfactory	Satisfactory	Satisfactory
Screw hole ossification	Absent	Absent	Mild	Moderate

Case 9

Name: Imran Khan

Age: 21 years

Sex: Male

Case history: Fracture of right parasymphysis with bilateral condylar fracture

Post-operative follow-up after treatment with bioresorbable plates and screws are shown in Table 9.

Case 10

Name: Abdul Khadir

Age: 18 years

Sex: Male

Case history: Fracture of left parasymphysis of mandible

Post-operative follow-up after treatment with bioresorbable plates and screws are shown in Table 10 (Figures 2, 3 and 5).

Table 7: Post-operative follow-up (Case 7).				
Evaluation	3 weeks	6 weeks	3 months	6 months
Clinical evaluation				
Swelling	Moderate	Moderate	Mild	Absent
Mucosal discoloration	Normal	Normal	Not present	Absent
Pain	Moderate	Absent	Nil	Absent
Occlusion relation	Class 1 molar	Class 1 molar	Class 1 molar	Class 1 molar
Fracture stability	Good	Good	Good	Good
Radiological evaluation				
Fracture healing	Satisfactory	Satisfactory	Satisfactory	Satisfactory
Screw hole ossification	Absent	Absent	Mild	Moderate

Table 8: Post-operative follow-up (Case 8).				
Evaluation	3 weeks	6 weeks	3 months	6 months
Clinical evaluation				
Swelling	Moderate	Mild	Mild	Absent
Mucosal discoloration	Normal	Normal	Not present	Absent
Pain	Moderate	Absent	Nil	Absent
Occlusion relation	Class 1 molar	Class 1 molar	Class 1 molar	Class 1 molar
Fracture stability	Good	Good	Good	Good
Radiological evaluation				
Fracture healing	Satisfactory	Satisfactory	Satisfactory	Satisfactory
Screw hole ossification	Absent	Absent	Mild	Moderate

Table 9: Post-operative follow-up (Case 9).				
Evaluation	3 weeks	6 weeks	3 months	6 months
Clinical evaluation				
Swelling	Moderate	Moderate	Mild	Mild
Mucosal discoloration	Normal	Normal	Not present	Absent
Pain	Moderate	Absent	Nil	Absent
Occlusion relation	Ant open bite with Class 1 molar relation	Ant open bite with Class 1 molar relation	Ant open bite with Class 1 molar relation	Ant open bite with Class 1 molar relation
Fracture stability	Good	Good	Good	Good
Radiological evaluation				
Fracture healing	Satisfactory	Satisfactory	Satisfactory	Satisfactory
Screw hole ossification	Absent	Absent	Mild	Moderate

Discussion

Injuries involving the facial bones are on the rise of late, with the increased number of automobiles and speed. Distortion of facial features due to trauma isolates the unfortunate individuals in present society.

The principle governing the treatment of jaw fractures has always been the restoration of the fragments to normal anatomy and stabilizing them in a position that will permit normal occlusion of the teeth as possible. The second principle is the restoration of facial contour and appearance of individual.⁹ Certain broad goals are desirable in the management of osseous fractures by internal fixation; they include sufficient strength of the material used, early osseous union and as little morbidity as possible. In the past, the use of metals for internal fixation has often led to the necessity of the removal during post-healing period. Many a times these materials have also contributed to secondary infections.

In this study bioresorbable PLA and PGA copolymer plates and screws were used to treat maxillomandibular fractures as an alternative to metal devices. All cases were systematically observed clinically for the parameters like swelling, mucosal discoloration, pain, occlusal disturbance and fracture stability and radiologically for fracture healing and screw hole ossification. At the end of 3 weeks, 6 weeks, 3 months, and 6 months of follow-up post-operatively.

In the present study, swelling was absent clinically in all cases at the end of 6 months of follow-up. The pain was absent in all the cases at the end of 6 months of follow-up in the present study, except in one case where a mild sensitivity of lower left first premolar was observed attributed to periapical infection associated with the same tooth which was not treated endodontically due to patient reluctance to undergo the treatment. In another study done by Ensildis *et al.* 57 patients complained of post-traumatic sequelae (hyperesthesia or dys/paresthesia lasting longer than 6 months.¹⁰ In a study done by Robert *et al.* in 35 patients with 50 fractures majority of patients had mild pain at the end of 1st week of follow-up and patients were pain-free at the end of 8 weeks¹¹ as observed similarly in the present study. This may be attributed to the sound surgical technique.

Table 10: Post-operative follow-up (Case 10).

Evaluation	3 weeks	6 weeks	3 months	6 months
Clinical evaluation				
Swelling	Moderate	Moderate	Mild	Mild
Mucosal discoloration	Normal	Normal	Not present	Absent
Pain	Moderate	Absent	Nil	Absent
Occlusion relation	Class I molar	Class I molar	Class I molar	Class I molar
Fracture stability	Good	Good	Good	Good
Radiological evaluation				
Fracture healing	Satisfactory	Satisfactory	Satisfactory	Satisfactory
Screw hole ossification	Absent	Absent	Mild	Moderate

In a study done by Laughlin *et al.* minor occlusal discrepancies were seen at 2 weeks of follow-up.¹¹ In another study done by Leonhardt *et al.* no long-term disturbance of occlusion was seen.³ A study by Krushna *et al.*, in 18 patients malocclusion was seen in 2 cases.¹² Study done by Bell and Kindsfater *et al.*¹³ in 295 patients anterior open bite was seen in one patient. These general findings are in confirmatory with the present study where no occlusion disturbances was seen in 10 patients except for one patient who reported with anterior open bite which could be attributed to presence of bilateral condylar fractures which was stabilized with maxillomandibular fixation and interarch elastics for 2 weeks and needed to be removed due to patients non-compliant with the procedure.

In a study done by Bryan and Craig¹³ in 295 patient's malunion was seen in 4 cases and non-union in 2 cases at the end of 4 years of follow-up. In another study done by Menon¹ fracture stability was adequate in all 16 patients at the end of 1-year of follow-up confirmatory with the present study where fracture stability was adequate in all 10 cases at the end of 6 months of follow-up.

Radiologically in the present study, fracture healing was found to be satisfactory in all 10 cases at the end of 6 months of follow-up period. But in a study done by Bryan and Craig¹³ in 295 patients malunion was observed in 4 cases and non-union in 2 cases at the end of 4 years of follow-up. A study by Robert *et al.* malunion¹¹ was seen in 3 patients at the end of 8 weeks of follow-up. However in a study done by Ferreti⁸ fractures healing was satisfactory in all 29 patients at the end of 1-year of follow-up as seen in the present study.

In all the 10 cases, radiologically screw-hole ossification was present at the end of 6 months of follow-up in the present study. A study done by Edwards *et al.*¹⁵ in 8 patients reported with screw hole ossification immediately after placement and remained unchanged at the end of 1-year post-operatively. In another study done by Menon in 20 patients¹ noted signs of screw holes in the resorbable group that disappeared at the end of 6 months as observed in the present study also.

A study done by Ensilidis *et al.* 8 patients reported with ectropian after subciliary approach.¹⁰ Another study done by Bryan and Craig in 208 patients one patient reported with ectropian and another patient with entropion.¹³ But in the present study entropion was seen only in 1-patient after 6 months of follow-up post-operatively.

Healing proceeded without any complications and without clinical or radiological deformity throughout the study period. No detrimental inflammatory or foreign body reactions were observed. But, in a study done by Bostman *et al.* using these plates and screws in 516 patients a clinically manifest foreign-body reaction occurred in 41 patients after an average of 12 weeks.¹⁶ Whereas, a study done by Bergsma *et al.* foreign body reactions were seen in 4 patients (total 10 patients) after a 3 years follow-up period post-operatively.¹⁷ In another study by Suuronen *et al.* no long-term clinical complications were encountered during the fifteen month follow-up⁵ and in another study done by Tarik *et al.* with a 3 years follow-up reported no serious complications² as seen in the present study.

Out of the 10 cases treated, sensitivity of left first premolar of mandible was noted in one case at the end of 6 months of follow-up, mild entropion was observed in the 3rd end of 6 months of follow-up and anterior open bite was noted in another case. Sensitivity of the case at the left first premolar was due the periapical infection associated with the same tooth which was not treated endodontically due to patient reluctance to undergo the treatment. Mild entropion could be attributed to the transconjunctival approach being used to access the fracture of infraorbital Rim and anterior open bite seen in one case could be attributed to presence of Bilateral condylar fractures which was stabilized with maxillomandibular fixation and interarch elastics for 2 weeks and needed to be removed due to patients non-compliant with the procedure.

In the present study, it is seen that bioresorbable self-reinforced PLA and PGA copolymer plates and screws are a promising fixation materials in the treatment of maxillomandibular fractures as they have overall least complication rate.

Conclusion

The bioresorbable self-reinforced PLA and PGA copolymer plates and screws can be successfully used in internal fixation of maxillofacial fractures. 10 cases of facial fractures treated with bioresorbable plates and screws have given good results with respect to adequate fixation and absorbability. The findings of this study indicate bioresorbable plates and screws proved to be a very promising material which could save considerable cost and eliminate the need for second surgery.

In the present study, it is seen that bioresorbable plates and screws are effective in the treatment of maxillomandibular fractures and with least complication rate.




Figure 1: Plating kit.

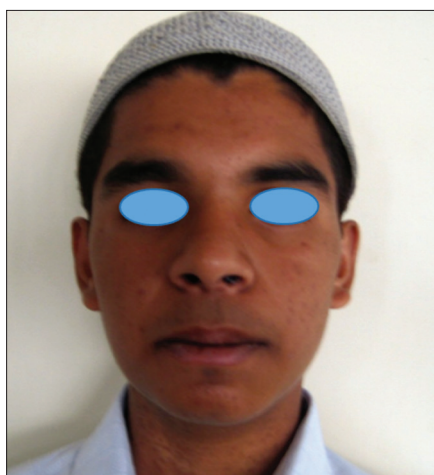

Figure 2: Pre-operative (extra oral).

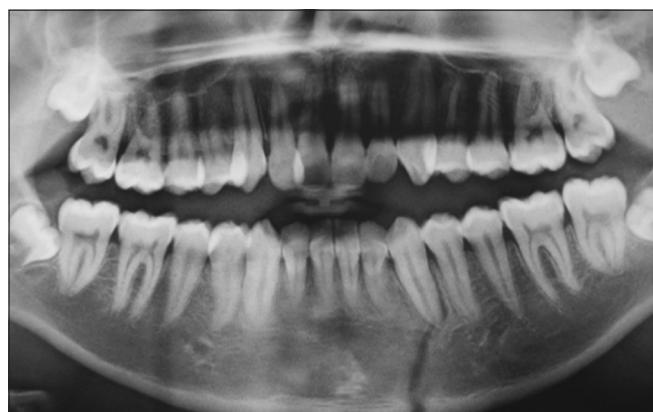

Figure 3: Pre-operative orthopantomogram showing fracture of left parasymphysis of mandible.

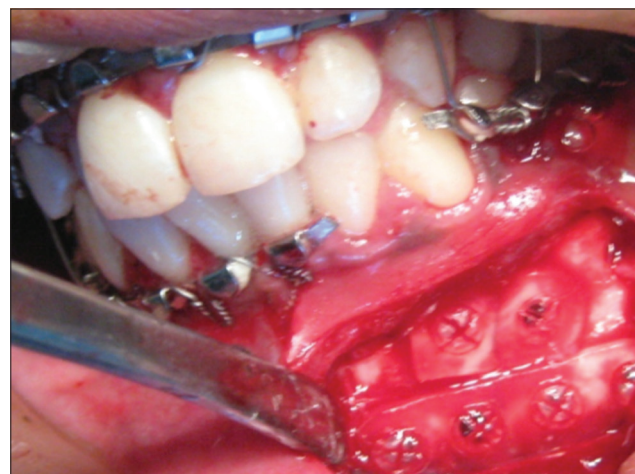

Figure 4: Internal fixation with self-reinforced polylactic and polyglycolic acid copolymer plates and screws - 2.5 mm.

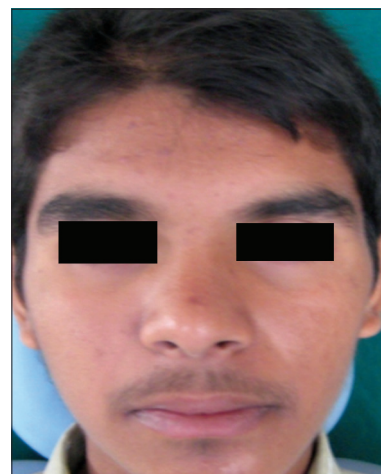

Figure 5: Post-operative 6 months extra oral examination.

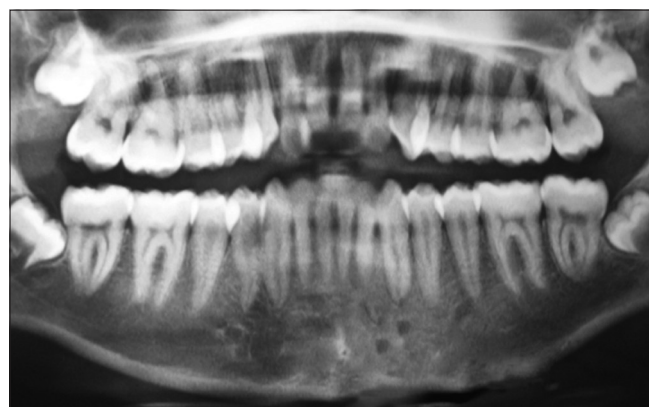

Figure 6: Post-operative 6 months orthopantomogram.

References

1. Menon CS, Chowdhary SK. Evaluation of bioresorbable vis a vis titanium plates & screws for craniofacial fractures and osteotomies. *Major J Armed Forces India* 2007;63;331-3.
2. Cavusoglu T, Yavuzer R, Basterzi Y, Tuncer S, Latifoglu O. Resorbable plate-screw systems: Clinical applications. *Ulus Travma Acil Cerrahi Derg* 2005;11(1):43-8.
3. Leonhardt H, Demmrich A, Mueller A, Mai R, Loukata R, Eckelt U. Inion compared with titanium osteosynthesis: A prospective investigation of the treatment of mandibular fractures. *Br J Oral Maxillofac Surg* 2008;46;631-4.
4. Wood GD. Inion biodegradable plates: The first century. *Br J Oral Maxillofac Surg* 2006;44(1):38-41.
5. Bergsma EJ, Rozema FR, Bos RR, de Bruijn WC. Foreign body reactions to resorbable poly(L-lactide) bone plates and screws used for the fixation of unstable zygomatic fractures. *J Oral Maxillofac Surg* 1993;51(6):666-70.
6. Suuronen R, Haers PE, Lindqvist C, Sailer HF. Update on

- bioresorbable polylactideplates in maxillofacial surgery. *Facial Plastic Surg* 1999;15:61-70.
7. de Lima JL Jr, de Goes KK, Ribeiro ED, Ferreira-Rocha J, da Cunha AL, Marzola VS. Treatment of mandibular fracture by bio-absorbable fixation. *Rev France Osteo* 2008;13(2):71-5.
8. Ferretti C. A prospective trial of poly-L-lactic/polyglycolic acid co-polymer plates and screws for internal fixation of mandibular fractures. *Int J Oral Maxillofac Surg* 2008;37(3):242-8.
9. Verbos J, Dupuis CC. From circumferential wiring o miniaturized plates and screws: The history of osteosynthesis of the mandible (with special reference to Dr. A. Lambotte). *Eur J Plast Surg* 2005;28:170-8.
10. Enislidis G, Lagogiannis G, Wittwer G, Glaser C, Ewers R. Fixation of zygomatic fractures with a biodegradable copolymer osteosynthesis system: Short- and long-term results. *Int J Oral Maxillofac Surg* 2005;34(1):19-26.
11. Laughlin RM, Block MS, Wilk R, Malloy RB, Kent JN. Resorbable plates for the fixation of mandibular fractures: A prospective study. *J Oral Maxillofac Surg* 2007;65(1):89-96.
12. Bhatt K, Roychoudhary A, Bhutia O, Seith A. Equivalence randomized controlled trail of bioresorbable versus titanium miniplates in treatment of mandibular fractures: A pilot study. *J Oral Maxillofac Surg* 2010;68:1842-8.
13. Bell BR, Kindsfater CS. The use of biodegradable plates and screws to stabilize facial fractures. *J Oral Maxillofac Surg* 2006;64:31-9.
14. Sharma V, Nemet A, Ghabrial R, Martin PA, Kourt G, Danks JJ, et al. A technique for medial canthal fixation using resorbable poly-L-lactic acid-polyglycolic acid fixation kit. *Arch Ophthalmol* 2006;124(8):1171-4.
15. Edwards RC, Kiely KD, Eppley BL. The fate of resorbable poly-L-lactic/polyglycolic acid (LactoSorb) bone fixation devices in orthognathic surgery. *J Oral Maxillofac Surg* 2001;59(1):19-25.
16. Böstman O, Hirvensalo E, Mäkinen J, Rokkanen P. Foreign-body reactions to fracture fixation implants of biodegradable synthetic polymers. *J Bone Joint Surg Br* 1990;72(1):592-6.
17. Suuronen R, Laine P, Pohjonen T, Lindqvist C. Sagittal ramus osteotomies fixed with biodegradable screws: A preliminary report. *J Oral Maxillofac Surg* 1994;52(7):715-20.