

Odontogenic Keratocysts in Gorlin–Goltz Syndrome: A Case Report

Satheesh Chandran¹, Karthikeyan Marudhamuthu², R Riaz³, Saravanan Balasubramaniam¹

Contributors:

¹Senior Lecturer, Department of Oral & Maxillofacial Surgery, Madha Dental College & Hospital, Kundrathur, Chennai, Tamil Nadu, India; ²Professor & Head, Department of Oral & Maxillofacial Surgery, Madha Dental College & Hospital, Kundrathur, Chennai, Tamil Nadu, India; ³Reader, Department of Oral & Maxillofacial Surgery, Madha Dental College & Hospital, Kundrathur, Chennai, Tamil Nadu, India.

Correspondence:

Dr. Chandran S. Department of Oral & Maxillofacial Surgery, Madha Dental College & Hospital, Kundrathur, Chennai - 600 069, Tamil Nadu, India. Phone: +91-9952973203/9865036532. Email: ch.satheesh@gmail.com

How to cite the article:

Chandran S, Marudhamuthu K, Riaz R, Balasubramaniam S. Odontogenic keratocysts in Gorlin–Goltz syndrome: A case report. J Int Oral Health 2015;S(1):76-79.

Abstract:

Gorlin–Goltz syndrome is an autosomal dominant inherited condition comprising the principle triad of basal cell carcinomas, multiple jaw keratocysts, and skeletal anomalies. The presence of jaw cysts are the early diagnostic feature of this syndrome, and this can be incidentally identified by routine radiographs. A patient presented with signs and symptoms of Gorlin–Goltz syndrome to us in her early stages.

Key Words: Carnoy's solution, enucleation, falx cerebri, keratocystic odontogenic tumor

Introduction

Nevoid basal cell carcinoma syndrome (NBCCS) or Gorlin–Goltz syndrome is an autosomal dominant inherited condition that exhibits high penetrance and variable expressivity; however this disorder can arise spontaneously. In 1960, Gorlin and Goltz described Gorlin–Goltz syndrome as a condition, comprising the principle triad of multiple BCC, odontogenic keratocysts (OKC) and skeletal anomalies.¹⁻³

In 1894, Jarisch and White reported this syndrome with patients having learning disabilities, scoliosis in multiple BCC. Gorlin and Goltz delineated a classical triad characterizing the diagnosis of this syndrome in 1960.^{4,5} Later this triad was modified by Rayner *et al.*, as the diagnostic criteria would include calcification of falx cerebri or palmer and planter pits.^{6,7}

This syndrome has numerous names as basal cell nevus syndrome, multiple NBCCS, multiple BCC syndrome multiple basaioma syndrome, jaw cyst basal cell tumor-skeletal anomaly syndrome and fifth phacomatosis.⁸

The main characteristic features of NBCCS are multiple OKC (75%), BCC (50-97%), bifid ribs (40%), palmer and planter pits (60-90%) and ectopic calcification of falx cerebri (37-79%).⁵

The prevalence is about 1/60000 live births, and it has both sporadic and familial incidence.⁹ This syndrome affects both male and female equally and are seen during the first, second, third decades of life.¹⁰ The approximate diagnosis age for NBCCS is 13 years while for BCC is 20 years.¹¹ The Ellsworth–Howord test is used to differentiate NBCCS from other disease status.¹²

The long-arm of chromosome 9q (22.3-q31) is the causative gene of NBCCS and has no apparent heterogeneity.¹³ The human homologue of the drosophila “patched” gene (PTCH) mutation results in loss of control of several genes that play a vital role in both organogenesis, carcinogenesis, and odontogenesis.^{14,15}

Case Report

A 19-year-old female patient reported to Department of Oral Maxillofacial Surgery, Madha Dental College, Chennai with a chief complaint of swelling and on and off pain in the left lower jaw region for the past 3 months. Extra-orally, a mild swelling was noticed in the left mandibular region of the face. Clinical examination revealed a broad nasal root.

There was a firm, non-tender and diffuse swelling in left mandibular third molar region intra-orally. An orthopantomogram (OPG) taken in 2011 showed well-defined radiolucency, of about 2 cm × 2 cm, with impacted third molar tooth in the left ramus of the mandible (Figure 1). An OPG taken in 2014 showed two well-defined radiolucencies in the mandible. One lesion was in left ramus with the impacted 38 tooth, of about 2 cm × 3 cm and another lesion was in the right body of mandible from 48 to 43, of about 5 cm × 2 cm (Figure 2).

A provisional diagnosis of multiple keratocystic odontogenic tumor (KCOT) was considered.

Under local anesthesia, Incisional biopsy was carried out in left ramus and right body of the mandible. The specimen was sent for pathological examination. Histopathological report revealed and confirmed the presence KCOT for our patient. Chest radiograph revealed fused ribs (Figure 3) and skull

radiograph showed calcification of falx cerebri (Figure 4). Lateral skull radiograph showed bridging of sella turcica (Figure 5). A possibility of NBCCS was considered.

Under general anesthesia, extended ward's incision was placed in the left ramus region. Cyst enucleation and surgical removal of 38 was performed. On the right body of the mandible, a crevicular incision with relieving incision was placed from 48 to 42. Extraction of 42, 43, 44, 45, 46, 47 and 48 with cyst

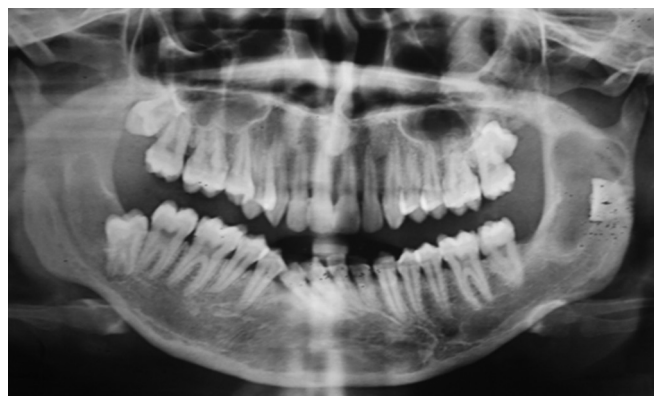


Figure 1: In 2011, orthopantomogram was taken which showed one well-defined radiolucency.

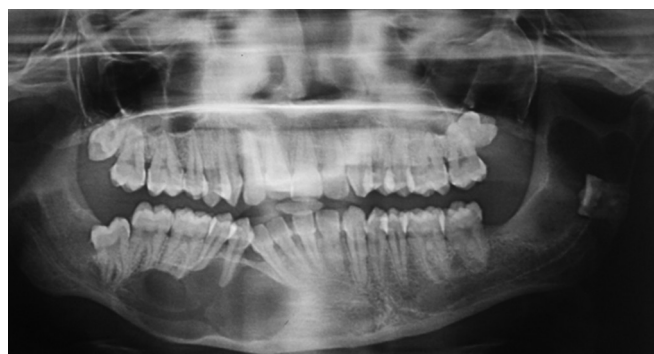

Figure 2: In 2014, orthopantomogram was taken, which showed two well-defined radiolucencies.

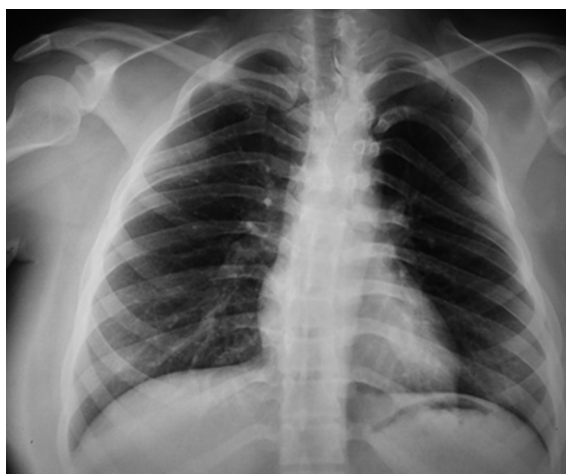


Figure 3: Fused ribs.

enucleation was performed. Carnoy's solution was applied on the exposed bony walls with preservation of the inferior alveolar neurovascular bundle in the cystic cavities for 3 min, and charring effect was achieved. The cystic cavities were then irrigated thoroughly with normal saline and closure done with 3-0 Vicryl. The specimens were sent for histopathological examination.

The patient was discharged with strict postoperative instructions that she should not involve in any contact sports activity in view of reduced mandibular osseous substances that may fracture. The patient is being followed-up for past 6 months on a regular basis without evidence of any recurrence.

Discussion

Various systems show evidence of abnormal changes in NBCCS comprising of the stomatologic system, skeletal system, ectopic calcification of the central nervous system (CNS), ocular system, genitor-urinary system, mesenteric cysts, skin, genitor-urinary system and cardiovascular system.^{8,16}

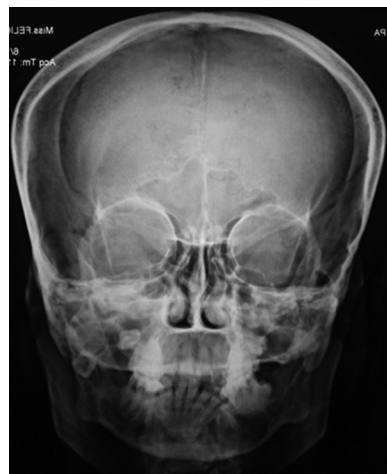

Figure 4: Calcification of falx cerebri.

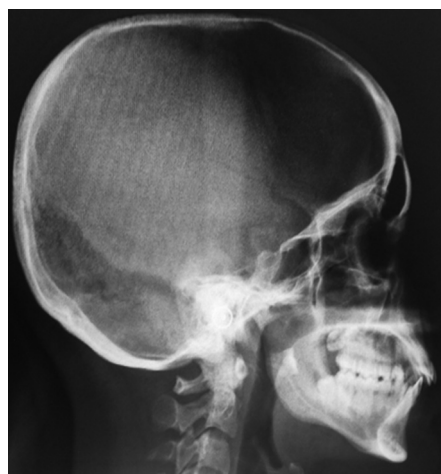

Figure 5: Bridging of sella turcica.

Manfredi *et al.*² reported other anomalies associated with this syndrome in 2004 and they are bifid ribs, splayed/fused ribs, rudimentary ribs, scoliosis, polydactyly, syndactyly, shortened 4th metacarpal, spina bifida, frontal bossing, temporal bossing, macrocephaly, falx cerebri calcification, bridged sella turcica, congenital hydrocephalus, mental retardation, medulloblastoma, cleft lip and/or palate, OKC, mandibular hyperplasia, ectopic position of tooth/teeth, impacted teeth, BCC, benign dermal cysts, calcified ovarian cysts, hypertelorism, ptosis, internal strabismus, glaucoma, cardiac fibroma, palmar and/or plantar pits. Routine blood investigations in these patients may show elevated levels of serum uric acid, cyclic adenosine mono phosphate, alkaline phosphate.

Even though the incidence of BCC is usually seen between second to third decades of life, some cases have been seen much more earlier.¹² More than 50% of NBCCS patients have shown to develop keratocysts, mostly in the first decade of life.⁸

The conclusion of NBCCS may be arrived when two major criteria or one major and two minor criteria are present for these patients.¹⁷ Initially Evans *et al.* formulated the diagnostic criteria based on frequent and/or specific features of the syndrome, which was later modified by Kimonis *et al.* in 1997.⁶

Major diagnostic criteria are OKC of the jaws proven by histopathology, bifid, fused or markedly splayed ribs, bilamellar calcification of the falx cerebri, first degree relatives with NBCCS, palmar or plantar pits (3 or more) and multiple BCCs or one under 20 years.

Minor diagnostic criteria are macrocephaly, congenital malformation such as cleft lip or palate, frontal bossing, hypertelorism, skeletal abnormalities like sprenge deformity, marked syndactyly of the digits, radiographic abnormalities like bridging of the sella turcica, ovarian fibroma and medulloblastoma.

Lo Muzio had suggested the following clinical examination protocols for patients with NBCCS.⁸

Diagnostic protocols in NBCCS

Family history

Past medical and dental history.

Clinical examinations of the following regions

Oral, skin, CNS, head circumference, inter-pupillary distance, eyes, genitourinary system, cardiovascular system, respiratory system, skeletal system, genetic testing.

X-ray

Chest A. P. and lateral skull, OPG, cervical and thoracic spine-A. P. and lateral, hands (for pseudo cysts), pelvic (female), ovarian ultrasound (female) for ovarian fibroma, Echocardiogram (children) for cardiac fibroma.

In our case, three major manifestations such as multiple OKCs, ectopic calcification of falx cerebri, fused ribs were identified, and one minor manifestation like bridging of sella turcica was identified and diagnosed as NBCCS.

A multidisciplinary approach (dentists, oral and maxillofacial surgeons, dermatologists and neurologists) is required for the diagnosis and management of this syndrome. In this syndrome, management is about adequate treatment of cysts and removal of tumours.¹⁸

KCOT is the first appearing sign of the syndrome. It is usually an incidental radiographic finding.¹⁹ The universal treatment protocol does not show much variation for KCOT with or without NBCCS. The major problem with syndromic KCOT's is that they have a high rate of recurrence than non-syndromic cysts.^{6,20} Thin lining and presence of multiple satellite cysts are the common findings in KCOT, which reduce the effectiveness of surgical treatment. Cryotherapy or Carnoy's solution is used as an adjunct for the management of syndromic KCOT. Carnoy's solution is safe and effective as it destroys epithelial islands or daughter cyst after enucleation. It is directly applied on the exposed osseous wall with a cotton swab for about 1-2 min and then thoroughly irrigated with sterile normal saline.²⁰⁻²²

Application of Carnoy's solution before the enucleation of the cyst proves to decrease the risk of KCOT recurrence. The solution is applied into the cystic cavity for 3 min after enucleation that significantly lowers the rate of recurrence (0-25%) without damaging inferior alveolar nerve in KCOT.^{22,23} The initial diagnosis, postoperative follow-up are the workhorse as the actual surgical treatment. A yearly OPG is suggested between the ages of 8-40 years that helps in identifying the development of new KCOTs or recurrence.²⁰

It is also suggested that NBCCS patients should have dermatological examination every 3-6 months with removal of basal cell nevus showing evidence of growth, ulceration or hemorrhage. Exposure to UV light to these patients should be decreased. The children with NBCCS must have neurological examination every 6 months as they are at a higher level of susceptibility to develop medulloblastoma.²⁴ The long-term complication of this syndrome includes the malignancy, oro-maxillofacial deformation, and destruction, which may be reduced if the diagnosis and treatment are made feasible at the earliest.

References

1. Gorlin RJ, Goltz RW. Multiple nevoid basal-cell epithelioma, jaw cysts and bifid rib. A syndrome. *N Engl J Med* 1960;262:908-12.
2. Manfredi M, Vescovi P, Bonanini M, Porter S. Nevoid basal cell carcinoma syndrome: A review of the literature. *Int J Oral Maxillofac Surg* 2004;33(2):117-24.

3. Deepa MS, Paul R, Balan A. Gorlin Goltz syndrome: A review. *J Indian Acad Oral Med Radiol* 2003;15:203-9.
4. Ljubenovi M, Ljubenovi D, Bini I, Jovanovi D, Stanojevi M. Gorlin-Goltz syndrome. *Acta Dermatovenerol Alp Pannonica Adriat* 2007;16(4):166-9.
5. Ortega García de Amezaga A, García Arregui O, Zepeda Nuño S, Acha Sagredo A, Aguirre Urizar JM. Gorlin-Goltz syndrome: Clinicopathologic aspects. *Med Oral Patol Oral Cir Bucal* 2008;13:E338-43.
6. Kimonis VE, Goldstein AM, Pastakia B, Yang ML, Kase R, DiGiovanna JJ, et al. Clinical manifestations in 105 persons with nevoid basal cell carcinoma syndrome. *Am J Med Genet* 1997;69(3):299-308.
7. Santana N, Yashodha Devi BK, Jatti D. Gorlin Goltz syndrome– A case report. *J Indian Dent Assoc* 2011;5(4):521.
8. LoMuzio L. Nevoid basal cell carcinoma syndrome (Gorlin syndrome). *Orphanet J Rare Dis* 2008;3(1):32.
9. Bakaeen G, Rajab LD, Sawair FA, Hamdan MA, Dallal ND. Nevoid basal cell carcinoma syndrome: A review of the literature and a report of a case. *Int J Paediatr Dent* 2004;14(4):279-87.
10. Evans DG, Farndon PA, Burnell LD, Gattamaneni HR, Birch JM. The incidence of Gorlin syndrome in 173 consecutive cases of medulloblastoma. *Br J Cancer* 1991;64(5):959-61.
11. Ramaglia L, Morgese F, Pighetti M, Saviano R. Odontogenic keratocyst and uterus bicornis in nevoid basal cell carcinoma syndrome: Case report and literature review. *Oral Surg Oral Med Oral Pathol Oral Radiol Endod* 2006;102(2):217-9.
12. Wood NK, Goaz PW, (Editors). Multiple separate well-defined radiolucencies. In: *Origins of Differential Diagnosis of Oral and Maxillofacial Lesions*, 5th ed. Philadelphia: Mosby; 1997. p. 382-4.
13. Hahn H, Wicking C, Zaphiropoulos PG, Gailani MR, Shanley S, Chidambaram A, et al. Mutations of the human homolog of *Drosophila* patched in the nevoid basal cell carcinoma syndrome. *Cell* 1996;85(6):841-51.
14. Soekarman D, Fryns JP, Casaer P, Van Den Berghe H. Increased head circumference and facial cleft as presenting signs of the nevoid basal-cell carcinoma syndrome. *Genet Couns* 1991;2(3):157-62.
15. Baliga SD, Rao SS. Nevoid-basal cell carcinoma syndrome: A case report and overview on diagnosis and management. *J Maxillofac Oral Surg* 2010;9(1):82-6.
16. Kiran NK, Tilak Raj TN, Mukunda KS, Rajashekar Reddy V. Nevoid basal cell carcinoma syndrome (Gorlin-Goltz syndrome). *Contemp Clin Dent* 2012;3(4):514-8.
17. Rayner CR, Towers JF, Wilson JS. What is Gorlin's syndrome? The diagnosis and management of the basal cell naevus syndrome, based on a study of thirty-seven patients. *Br J Plast Surg* 1977;30(1):62-7.
18. Guruprasad Y, Prabhu PR. Gorlin-Goltz syndrome with situs oppositus. *Natl J Maxillofac Surg* 2010;1(1):58-62.
19. Hegde S, Shetty SR. Radiological features of familial Gorlin-Goltz syndrome. *Imaging Sci Dent* 2012;42(1):55-60.
20. Farndon PA, Del Mastro RG, Evans DG, Kilpatrick MW. Location of gene for Gorlin syndrome. *Lancet* 1992;339(8793):581-2.
21. Voorsmit RA, Stoelinga PJ, van Haelst UJ. The management of keratocysts. *J Maxillofac Surg* 1981;9(4):228-36.
22. Stoelinga PJ. The treatment of odontogenic keratocysts by excision of the overlying, attached mucosa, enucleation, and treatment of the bony defect with carnoy solution. *J Oral Maxillofac Surg* 2005;63(11):1662-6.
23. Tolstunov L, Treasure T. Surgical treatment algorithm for odontogenic keratocyst: Combined treatment of odontogenic keratocyst and mandibular defect with marsupialization, enucleation, iliac crest bone graft, and dental implants. *J Oral Maxillofac Surg* 2008;66(5):1025-36.
24. Peled M, Kohn Y, Laufer D. Conservative approach to unerupted teeth within cystic lesions in Gorlin's syndrome. *Am J Orthod Dentofacial Orthop* 1991;99(4):294-7.