

## Comparison of Cone Beam Computed Tomography, Orthopantomography with Direct Ridge Mapping for Pre-Surgical Planning to Place Implants in Cadaveric Mandibles: An *Ex-Vivo* Study

G S Amarnath<sup>1</sup>, Ullash Kumar<sup>2</sup>, Mohammed Hilal<sup>3</sup>, B C Muddugangadhar<sup>3</sup>, Kopal Anshuraj<sup>2</sup>, C S Shruthi<sup>4</sup>

### Contributors:

<sup>1</sup>Professor, Department of Prosthodontics Including Crown and Bridge and Implantology, M R Ambedkar Dental College and Hospital, Bengaluru, Karnataka, India; <sup>2</sup>Post-graduate Student, Department of Prosthodontics Including Crown and Bridge and Implantology, M R Ambedkar Dental College and Hospital, Bengaluru, Karnataka, India; <sup>3</sup>Reader, Department of Prosthodontics Including Crown and Bridge and Implantology, M R Ambedkar Dental College and Hospital, Bengaluru, Karnataka, India; <sup>4</sup>Reader, Department of Prosthodontics including Crown and Bridge and Implantology, M R Ambedkar Dental College and Hospital, Bengaluru, Karnataka, India

### Correspondence:

Dr. Ullash Kumar, Department of Prosthodontics Including Crown and Bridge and Implantology, M R Ambedkar Dental College and Hospital, Bengaluru, Karnataka, India. Phone: +91-9886425114. Email: dr.ullashkumar@gmail.com

### How to cite the article:

Amarnath GS, Kumar U, Hilal M, Muddugangadhar BC, Anshuraj K, Shruthi CS. Comparison of cone beam computed tomography, orthopantomography with direct ridge mapping for pre-surgical planning to place implants in cadaveric mandibles: An *ex-vivo* study. J Int Oral Health 2015;S(1):38-42.

### Abstract:

**Background:** Implant treatment is today a common and most widely accepted prosthetic therapy worldwide. The quality and quantity of the bone available at the anticipated implant site is of prime importance. Accurate measurement of alveolar bone and adjacent anatomic structures are of paramount importance in implant insertion. Proper pre-surgical assessment requires precise radiographic visualization of anatomic structures and pathologic conditions. However, the concern for radiation exposure has also grown.

**Materials and Methods:** A total of 15 partially or completely edentulous human cadaveric mandibles were used which were further subdivided into three further groups for cone-beam computed tomography (CBCT), orthopantomography (OPG), and direct measurements (DM). Mandibles were prepared for each sample and subjected to radiographs according to the respective techniques, and radiographic measurements were done using the appropriate software. The cadaveric mandibles were then sectioned, and the actual measurements were done using a digital vernier caliper.

**Results:** Analysis of variance test revealed that there was no significant difference among the three different measurements techniques.

**Conclusion:** A sizable portion of the CBCT measurements with respect to width showed slight overestimation when compared to DMs. There were no statistically significant differences found

between CBCT, OPG, and DM when height was taken into consideration.

**Key Words:** Cone beam computed tomography, direct measurements, implant orthopantomography

### Introduction

The discovery of X-rays by Roentgen in 1895 revolutionized dentistry.<sup>1</sup> In the last decade, three dimensional technology was refined for integration into routine dental practice with the discovery of cone beam computed tomography (CBCT).

A risk of nerve infiltration and maxillary sinus perforation exists originating from inappropriate pre-surgical planning due to the innate discrepancy between radiographic measurements and real dimensions. Precise radiographic assessment of available alveolar bone and identification of characteristic bone morphology are of prime importance for dental implant placement. Radiation dose, magnification rate, and specific indications are to be considered when selecting the type of radiographic modality.<sup>2</sup>

One commonly used clinical method for assessing edentulous ridges transversely is ridge mapping, in which sharp-beaked calipers are used to measure the faciolingual width of the residual bony ridge at the proposed implant site.<sup>3</sup>

The purpose of this study was to determine the reliability of pre-surgical planning based on the use of two types of radiographic image (orthopantomography [OPG] and CBCT) and ridge mapping to analyze the differences in measurements between radiographic images and real specimens.

### Materials and Methods

This study was carried out in Department of Prosthodontics, M R Ambedkar Dental College and Hospital, Bengaluru. The CBCT and OPG scans were done at Oral D Diagnostic and Scanning Centre, Bengaluru.

Fifteen partially or completely dry edentulous adult human cadaveric mandible samples were selected from the Department of Anatomy, Ambedkar Medical College and Hospital, Bangalore, for this study and were used to examine the values of CBCT, OPG, and direct measurements (DM). The sex and age of these samples were unknown. The posterior teeth were extracted in case there was a tooth

present on the cadaveric mandible. For each specimen, a single posterior mandibular implant site was selected and marked on the specimen with a line drawn transverse to the dental arch. The following points were marked along this line on the buccal and lingual aspects of the ridge:

- 2 mm - From the crest of the alveolar ridge.
- 5 mm - From the crest of the alveolar ridge.
- 8 mm- From the crest of the alveolar ridge.

Areas extending from first premolar to the third molar were identified for each mandible bilaterally. Three pairs of buccal/lingual measurement points were defined at the site of implant placement and marked on the mandible located at 2 mm, 5 mm, and 8 mm from the summit of the crest of the alveolar ridge. Modeling wax was used to stabilize a steel ball of 4 mm diameter on the crest of the ridge and the gutta-percha points at those reference points. Gutta-percha was used to provide radiopaque landmarks indicating the locations for comparative radiographic ridge width measurements. The steel ball at the crest of the ridge was used as a reference point to calculate the height of the mandible. The guides (gutta-percha) used for the measurements to the desired heights from the crest of the ridge was measured using a digital vernier caliper with 0.01 mm sensitivity. Gutta-percha points were fixed at the specified locations using super glue.

These specimens were then subjected to CBCT, OPG. The mandibles were then sectioned in the marked planes using a 0.6 mm wide band saw. The distance between those landmarks on the mandibles was measured using a digital vernier caliper with an accuracy of 0.01 mm.

**CBCT measurements**

The mandibles were stabilized on a polystyrene stand and scanned by a CBCT unit operating at 120 kVp, 3-8 mA, and 0.5 mm nominal focal spot size. The data were imported into implant planning software (DICOM). The images of the planes were transferred to an image storage and measurement system (Med3D) and calibrated using the implant planning software reference gauge lines. The distance on the radiographic image was measured with a tool built into the image storage and measurement software. The CBCT measurements for calculating the width was done at 2 mm, 5 mm, and 8 mm buccolingually and the height of the mandible was measured from the inferior point of the steel ball to the most inferior point on the mandible.

**OPG measurements**

The mandibles were stabilized on a polystyrene stand and scanned by an OPG unit. Digital panoramic images were taken at 57 kV, 2 mA with an exposure time of 17.6 s. Using software, the movements of the machine can be controlled to obtain accurate locations and angles of the objective plane. The distance on the radiographic image was measured with a

tool built into the image storage and measurement software. The height of the mandible on the OPG with the help of the software was measured from the inferior point of the steel ball to the most inferior point on the mandible.

**DMs**

The mandibles were sectioned in the marked planes using a 0.6 mm wide band saw. Landmarks were identified on the fresh specimens and their respective images. The distance between those landmarks on the fresh mandibles was measured using a digital vernier caliper with an accuracy of 0.01 mm. Measurements made on the actual mandible served as gold standard. Three linear measurements were recorded buccolingually on either side at 2 mm, 5 mm, and 8 mm from the crest of the alveolar ridge to record the width of the bone using the digital vernier caliper. The gutta-percha markings were used as reference points for all these measurements. The distance between the occlusal landmarks, i.e. the inferior point of the steel ball to the inferior border of the mandible was also recorded using a digital vernier caliper to record the height of the mandible.

**Statistical analysis**

The data collected were analyzed using the analysis of variance (ANOVA) to determine the technique, which gives the result closest to the actual values.

**Results**

The mandibles were prepared and were subdivided further into three groups: CBCT (Group 1), OPG (Group 2), and DMs (Group 3) techniques.

The mean and standard deviations of the measurements with respect to height and width are depicted in Graphs 1-3 and Tables 1 and 2.

With respect to bone height in cadaveric mandibles, the mean ± standard deviation (SD) for Group 1 for the right side of the mandible was 26.09 ± 3.15 and 26.27 ± 2.88 for the left side whereas for Group 2 it was 26.25 ± 2.94 and 26.43 ± 3.03, respectively. In Group 3 the mean ± SD for the right side was 25.67 ± 3.19 and 25.98 ± 2.64 for the left side.

There were no statistically significant differences seen when bone height in the cadaveric mandible were compared in all the three groups using two-way analysis of variance (Graph 1).

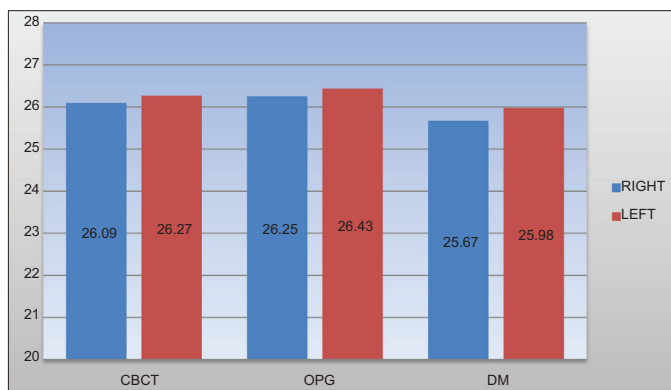
Table 1: Mean and SD of CBCT, OPG, and DM with respect to bone height in the cadaveric mandible.			
Groups	Number of samples (n)	Mandible (mean±SD)	
		Right	Left
Group 1	30	26.09±3.15	26.27±2.88
Group 2	30	26.25±2.94	26.43±3.03
Group 3	30	25.67±3.19	25.98±2.64

SD: Standard deviation, CBCT: Cone beam computed tomography, OPG: Orthopantomography, DM: Direct measurements

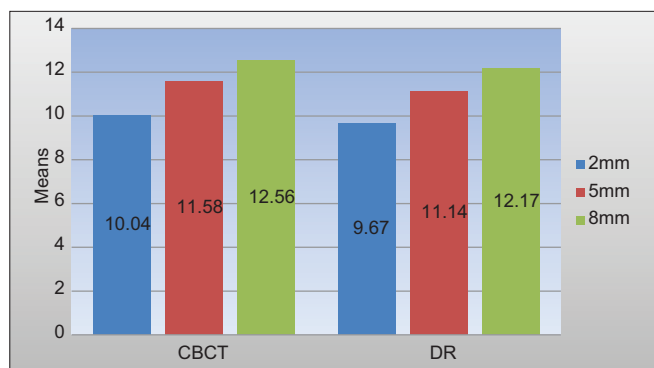
Table 2: Mean and SD of CBCT and DM with respect to bone width in the cadaveric mandible.

Groups	Right mandible (mean±SD)			Left mandible (mean±SD)		
	2 mm	5 mm	8 mm	2 mm	5 mm	8 mm
Group 1	10.04±1.45	11.58±1.43	12.56±1.24	9.95±1.22	11.53±0.96	12.52±1.11
Group 3	9.67±1.41	11.14±1.50	12.17±1.26	9.69±1.10	11.26±0.99	12.22±1.20

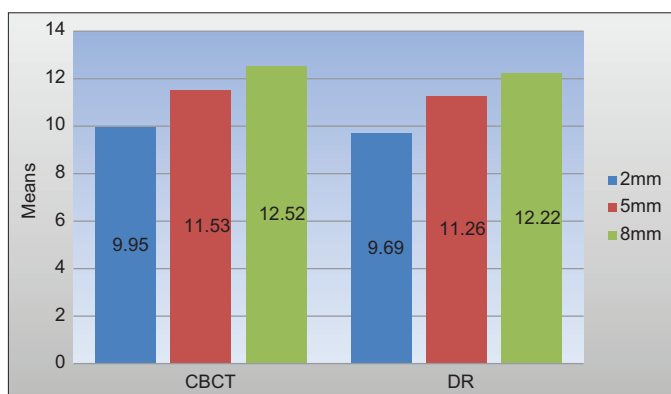
SD: Standard deviation, CBCT: Cone beam computed tomography, OPG: Orthopantomography, DM: Direct measurements



Graph 1: Comparison of cone beam computed tomography, orthopantomography, and direct measurements with respect to bone height in the cadaveric mandible.



Graph 2: Comparison of cone beam computed tomography and direct measurements with respect to bone width in the cadaveric mandible (right).



Graph 3: Comparison of cone beam computed tomography, and direct measurements with respect to bone width in the cadaveric mandible (left).

In relation to width in cadaveric mandibles the mean ± SD for Group 1 for the right side of the mandible at 2 mm was 10.04 ±

1.45, whereas for Group 3 at 2 mm it was 9.67 ± 1.41, at 5 mm for Group 1 the mean ± SD is 11.58 ± 1.43 and 11.14 ± 1.50 for Group 3. At 8 mm for Group 1 the mean ± SD was 12.56 ± 1.24 and for Group 3 12.17 ± 1.26.

The mean ± SD with respect to width on the left side of the mandible for Group 1 at 2 mm was 9.95 ± 1.22 whereas for Group 3 it was 9.69 ± 1.10. At 5 mm it was 11.53 ± 0.96 for Group 1 and 11.26 ± 0.99 for Group 3. The mean ± SD at 8 mm for Group 1 was 12.52 ± 1.11 whereas for Group 3 it was 12.22 ± 1.20.

The comparison of CBCT, OPG, and DM with respect to bone height and width in cadaveric mandibles is depicted in Tables 3 and 4. There were no statistically significant differences seen when bone width in the cadaveric mandible were compared in all the three groups using two-way analysis of variance (Graphs 2 and 3). However, the significant percentage of sites showed an overestimation of at least 0.5 mm.

**Discussion**

Implant treatment is today a common prosthetic therapy worldwide. The quality and quantity of bone available at the anticipated implant site is of importance during planning and follow-up after implant placement.<sup>4</sup> Accurate pre-surgical planning assessment requires precise radiographic visualization of anatomic structures and pathologic conditions.<sup>5</sup> Panoramic radiographs are a worldwide used standard radiographic examination tool when planning treatment with implants as they impart low radiation dosage while giving the best radiographic survey. Panoramic radiographs are reliable to evaluate the available bone height before placing implants in the mandibular posterior region.<sup>6</sup>

The terminology “cone beam” refers to the conical shape of the beam that scans the patient in a circular path around the vertical axis of the head. The physical size and shape of CBCT units has paralleled the panoramic pathway. One of the very first commercially available cone beam machines, New Tom 9000 (QR srl, Verona, Italy), was a large unit that scanned the patient lying in the supine position. It was followed by New Tom 3G.<sup>7</sup> Eventually smaller units with better scanner quality that fit into the dental office space and overhead budgets have replaced the older ones.<sup>8</sup> Wilson introduced the concept of ridge mapping.<sup>9</sup>

This study was performed to compare the diagnostic information gathered by CBCT imaging, OPG and DMs for

Table 3: Comparison of CBCT, OPG, and DM with respect to bone height in the cadaveric mandible.

Source	Dependent variable (mandible)	Type III sum of squares	df	Mean square	F	P value
Corrected model	Right	2.695	2	1.348	0.140	0.869
	Left	1.532	2	0.766	0.094	0.911
Intercept	Right	30428.841	1	30428.841	3168.933	0.000
	Left	30963.728	1	30963.728	3785.764	0.000
Groups	Right	2.695	2	1.348	0.140	0.869
	Left	1.532	2	0.766	0.094	0.911
Error	Right	403.294	42	9.602		
	Left	343.518	42	8.179		
Total	Right	30834.829	45			
	Left	31308.777	45			

P<0.05 significant using two-way analysis of variance. CBCT: Cone beam computed tomography, OPG: Orthopantomography, DM: Direct measurements

Table 4: Comparison of CBCT and DM with respect to bone width in the cadaveric mandible.

Corrected model	Mean±SD					
	Right mandible			Left mandible		
	2 mm	5 mm	8 mm	2 mm	5 mm	8 mm
Type III sum of squares	0.979	1.439	1.091	0.504	0.549	0.672
Df	1	1	1	1	1	1
Mean square	0.979	1.439	1.091	0.504	0.549	0.672
F	0.474	0.669	0.693	0.372	0.571	0.499
P value	0.497	0.420	0.412	0.547	0.456	0.486

P<0.05 significant using multivariate analysis of variance. SD: Standard deviation, CBCT: Cone beam computed tomography, DM: Direct measurements

pre-surgical implant dentistry assessment to establish a basis to weigh the potential diagnostic and therapeutic benefits of each imaging modality in implant dentistry.

The model, which was used in the study enabled DMs of the actual distances that are not possible in humans. Allen *et al.* reported that direct caliper measurement following the exposure of the bone surgically seemed to be the most accurate measurement and could be considered the gold standard.<sup>4</sup> A comparison of the CBCT to direct caliper measurements in our study showed deviations within 0.5 mm. This was in accordance with the study done by Chen *et al.* where the bucco-lingual width was overestimated using CBCT images. This seemed to be related to difficulties in defining the cortical borders of the alveolar process. Another problem related to the CBCT measurements was the difficulty in finding single buccal, lingual cross-sectional images that passed through the center of all six gutta-percha points.<sup>10</sup>

In a study reported by Hu *et al.* the measurement error in CBCT did not show any significant difference from that in digital panoramic radiography, which is in accordance to this present study. This shows that there will be a lesser number of errors when pre-surgical plans are made using dental panoramic radiography in the mandible. Identifying the superior border of the mandible is easier than the inferior border of the maxillary sinus because the mandibular canal is easily identifiable in most of the cases. This easy detection of the mandibular canal will allow dental surgeons to place implants in the posterior

mandibular region without any surgical issues as long as the bucco-lingual width is measured carefully. DM using calipers is recommended either intraorally or extraorally on a study model.<sup>11</sup>

This study there was a slight increase of 0.5 mm in CBCT measurements compared to DMs. Chen *et al.* in their study found overestimations of up to 8 mm in a study conducted in humans. Several factors might have caused these substantial overestimations. First, radiographic and DMs were not obtained in the same manner; CBCT scans were obtained with radiographic guides in the jaws, whereas DMs were performed without the radiographic guides following the surgical exposure of the bone. Second, DMs in patients could have been impaired owing to inherent difficulties of accessibility and surgical conditions, leading to potential inconsistencies between radiographic and DMs. Moreover, since the study was performed in patients, the reliability of CBCT for the evaluation of the vertical dimension of the alveolar bone could not be determined. A study was done by Halperin-Sternfeld *et al.* to compare linear measurements made on CBCT images to DMs in *ex-vivo* porcine mandibles found a good correlation between CBCT and DMs. They found out that, a sizable portion of the CBCT measurements showed overestimations, indicating that the actual linear distances may be smaller than their radiographic appearance which correlates with the present study.<sup>12</sup>

A study conducted by Correa *et al.* where dental implant sizes were planned with OPG, CBCT-generated panoramic images, and CBCT cross-sectional images, found out that there was no significant difference in implant length among the three imaging modalities. It hardly mattered for the change in implant step sizes whether CBCT-cross-sectional images was compared to digital panoramic radiography or CBCT-generated panoramic images, which were in accordance with the present study.<sup>13</sup>

Dula *et al.* did a study on decision making criteria for radiographic assessment of implant patients stated that according to current radiation protection regulations, both



nationally and internationally, are based on justification and the as low as reasonably achievable principle.

This implies that every radiographic examination must be carried out to the benefit of the patient by application of the lowest possible dose.

Therefore, the selection of imaging technique is already a part of the radiation protection measures.<sup>14</sup>

### Conclusion

The most frequently used imaging modalities in implant dentistry are proposed based on the clinical need and biologic risks associated with the patient. CBCT and OPG are two common imaging modalities used in implant dentistry. Direct mapping also provides reliable information to predict width of the bone available for implantation.

Each application of radiographic technology must be taken into account its potential risks and the net benefit it produces. Radiation dosages for the investigated CBCT device are three times higher than those seen in OPG. For the present study, a sizable portion of the CBCT measurements with respect to width showed slight overestimations, indicating that the actual linear distances may be smaller than their radiographic appearance. In clinical implant practice, this may result in potential injury to vital anatomic structures adjacent to the implant site. There was no significant statistical difference between the three measurement methods when height was taken into account. Pre-surgical planning can be performed safely using OPG in mandible; however, pre-surgical planning using CBCT is recommended in the maxilla when a structure in the buccolingual location needs to be evaluated because this imaging modality supplies buccolingual information that cannot be obtained from OPG.

### References

1. Pette GA, Norkin FJ, Ganeles J, Hardigan P, Lask E, Zfaz S, et al. Incidental findings from a retrospective study of 318 cone beam computed tomography consultation reports. *Int J Oral Maxillofac Implants* 2012;27(3):595-603.
2. Hu KS, Choi DY, Lee WJ, Kim HJ, Jung UW, Kim S. Reliability of two different presurgical preparation methods for implant dentistry based on panoramic radiography and cone-beam computed tomography in cadavers. *J Periodontal Implant Sci* 2012;42(2):39-44.
3. Perez LA, Brooks SL, Wang HL, Eber RM. Comparison of linear tomography and direct ridge mapping for the determination of edentulous ridge dimensions in human cadavers. *Oral Surg Oral Med Oral Pathol Oral Radiol Endod* 2005;99(6):748-54.
4. Allen F, Smith DG. An assessment of the accuracy of ridge-mapping in planning implant therapy for the anterior maxilla. *Clin Oral Implants Res* 2000;11(1):34-8.
5. Tepper G, Hofschneider UB, Gahleitner A, Ulm C. Computed tomographic diagnosis and localization of bone canals in the mandibular interforaminal region for prevention of bleeding complications during implant surgery. *Int J Oral Maxillofac Implants* 2001;16(1):68-72.
6. Dula K, Mini R, van der Stelt PF, Buser D. The radiographic assessment of implant patients: Decision-making criteria. *Int J Oral Maxillofac Implants* 2001;16(1):80-9.
7. Miles DA, Danforth RA. Cone beam computed tomography: From capture to reporting. *Dent Clin North Am* 2014;58(3):ix-x.
8. Naitoh M, Kawamata A, Iida H, Ariji E. Cross-sectional imaging of the jaws for dental implant treatment: Accuracy of linear tomography using a panoramic machine in comparison with reformatted computed tomography. *Int J Oral Maxillofac Implants* 2002;17(1):107-12.
9. Kullman L, Al-Asfour A, Zetterqvist L, Andersson L. Comparison of radiographic bone height assessments in panoramic and intraoral radiographs of implant patients. *Int J Oral Maxillofac Implants* 2007;22(1):96-100.
10. Loubele M, Guerrero ME, Jacobs R, Suetens P, van Steenberghe D. A comparison of jaw dimensional and quality assessments of bone characteristics with cone-beam CT, spiral tomography, and multi-slice spiral CT. *Int J Oral Maxillofac Implants* 2007;22(3):446-54.
11. Kaya Y, Sencimen M, Sahin S, Okcu KM, Dogan N, Bahcecitapar M. Retrospective radiographic evaluation of the anterior loop of the mental nerve: Comparison between panoramic radiography and spiral computerized tomography. *Int J Oral Maxillofac Implants* 2008;23(5):919-25.
12. Chen LC, Lundgren T, Hallström H, Cherel F. Comparison of different methods of assessing alveolar ridge dimensions prior to dental implant placement. *J Periodontol* 2008;79(3):401-5.
13. Baba R, Ueda K, Okabe M. Using a flat-panel detector in high resolution cone beam CT for dental imaging. *Dentomaxillofac Radiol* 2004;33(5):285-90.
14. Peker I, Alkurt MT, Michcioglu T. The use of 3 different imaging methods for the localization of the mandibular canal in dental implant planning. *Int J Oral Maxillofac Implants* 2008;23(3):463-70.