

Correlation of Condylar Guidance Determined by Panoramic Radiographs to One Determined by Conventional Methods

A Sowjanya Godavarthi¹, M C Suresh Sajjan², A V Rama Raju³, P Rajeshkumar⁴, Avernani Premalatha⁵, Narayana Chava⁶

Contributors:

¹Senior Lecturer, Department of Prosthodontics & Implantology, Gitam Dental College, Vishakapatnam, Andhra Pradesh, India; ²Professor and Head, Department of Prosthodontics & Implantology, Vishnu Dental College, Bhimavaram, Andhra Pradesh, India; ³Professor, Department of Prosthodontics & Implantology, Vishnu Dental College, Bhimavaram, Andhra Pradesh, India; ⁴Senior Lecturer, Department of Prosthodontics & Implantology, GSL Dental College, Rajamundry, Andhra Pradesh, India; ⁵Reader, Department of Prosthodontics, Dr. Sudha & Nageswararao Sidhhartha Dental Sciences, Krishna, Andhra Pradesh, India; ⁶Assistant Professor, Department of Prosthodontics, St. Joseph Dental College, Eluru, Andhra Pradesh, India.

Correspondence:

Dr. Godavarthi AS. Department of Prosthodontics & Implantology, Gitam Dental College, Vishakapatnam - 530 045, Andhra Pradesh, India. Phone: +91-9949919784. Email: sowjigodavarthi@yahoo.com.

How to cite this article:

Godavarthi AS, Sajjan MC, Raju AV, Rajeshkumar P, Premalatha A, Chava N. Correlation of condylar guidance determined by panoramic radiographs to one determined by conventional methods. J Int Oral Health 2015;7(8):123-128.

Abstract:

Background: To evaluate the feasibility of using panoramic radiographs as an alternative to an interocclusal recording method for determining the condylar guidance in dentate and edentulous conditions.

Materials and Methods: 20 dentulous individuals with an age range of 20-30 years and 20 edentulous patients of 40-65 years were selected. An interocclusal bite registration was done in protrusive position for all the subjects. Orthopantomographs were made for all patients in open mouth position. Hanau articulator was modified to record the angulations to the accuracy of 1°. Tracing of glenoid fossa on radiograph was done to measure the condylar guidance angles. Readings were recorded and analyzed by Friedman's test and t-test.

Results: Condylar guidance values obtained by the interocclusal method and radiographic method in dentate individuals on the right side and left side 40.55°, and 37.1°, and 40.15°, and 34.75°, respectively. In the edentulous individuals, the values on the right side and left side was 36.7° and 36.1° and 35.95° and 33.6°, respectively. The difference was statistically significant ($P = < 0.001$) in dentate group and was not statistically significant ($P = 0.6493$) in edentulous group.

Conclusion: Panoramic radiograph can be used as an alternative to interocclusal technique only in edentulous patients. Further studies comparing panoramic radiograph to jaw tracking devices would substantiate the results of this study.

Key Words: Condylar guidance, interocclusal records, panoramic radiograph

Introduction

Programming of the semi-adjustable articulator is an additional step that is deemed mandatory for the fabrication of good removable or fixed prosthesis. Programming of the semi-adjustable articulator refers to adjusting the horizontal condylar guidance and lateral condylar guidance and incisal guidance.

Condylar guidance is described as the mandibular guidance generated by the condyle and articular disc traversing the contour of anterior slope of glenoid fossae or, synonymously, as the mechanical form located in the upper posterior region of the articulator that controls the movement of the mobile member.¹ The angle at which the condyle moves away from the horizontal reference plane is referred to as the condylar guidance. This angle varies from person to person and from one side to the other.² The goal of registering this condylar guidance is to program the articulator for simulating the patient's condylar movements as accurately as possible.

Various clinical methods for recording the sagittal condylar guidance are intraoral check bite method, graphic tracings, and functional recordings.³ With the interocclusal check bite method errors can creep in due to variation in the properties, and manipulation of the recording material such as distortion of the recording material, and poor adaptation of the casts to the wax.⁴ Another problem noted with the wax protrusive technique was that patients had a difficulty closing precisely in protrusion, which was attributed to a lack of voluntary neuromuscular control. Regardless of the material used, angle changes with the degree of protrusion and that intraoral record represents only one point along the condylar path. Accuracy of graphic tracings is affected by patient-related factors such as neuromuscular control of the individual, stability of record bases as well as ability of recording media.⁵

The introduction of optoelectronic devices has solved some of these problems associated with the clinical methods for determining the condylar guidance.⁶ However, clinical usage of these devices requires good neuromuscular control of the patient, skill of the operator, and it is a consuming procedure. Usage of such devices is not readily feasible in developing

countries like India since the equipment expense is not economical.

A very early attempt was made to record the condylar path by radiographs by Boos in 1951. He used temporomandibular joint (TMJ) radiographs to determine the condylar guidance angle.⁴ Orthopantomographs (OPG) are one of the commonly used diagnostic tools in dentistry. Anthropometric studies have shown the use of panoramic radiographs to measure the condylar guidance. Panoramic radiographic image accurately represents the outline of articular eminence. It may be used as an aid in setting the condylar guidance inclination of a semi-adjustable articulator. The use of panoramic radiographs can overcome the shortcomings of the conventional clinical methods used to determine the condylar guidance. The clinical implication of these studies needs to be compared for reasonable accuracy. Therefore the main aim of this study is to evaluate the feasibility to use the panoramic radiographs to determine the condylar guidance in comparison with the conventional clinical methods for reasonable accuracy.

Objectives of the study

1. To determine the condylar guidance on panoramic radiographs in dentate and edentulous subjects
2. To determine the condylar guidance by conventional clinical method in dentate and edentulous subjects
3. To compare the values obtained from panoramic radiographs with the values obtained by a conventional technique.

Materials and Methods

40 subjects comprising of 20 dentulous with age group ranging from 20 to 30 years, and 20 edentulous subjects with age group ranging from 40 to 65 years were randomly selected for the study with the following inclusion criteria. Patients free of TMJ disorders, with good neuromuscular control, dentulous subjects with a complete set of teeth, edentulous subjects with moderately formed ridges. The exclusion criteria include patients with a history of orthodontic treatment, patients with deep bite and anterior malocclusion, patients with prognathic and retrognathic mandible, patients with a gross facial deformity. The subjects were divided into 2 groups. Group I comprising of 20 dentulous subjects, and Group II comprising of 20 edentulous subjects.

The two groups were subdivided into,

Group, I A were condylar guidance angle was determined by a conventional technique.

Group, I B were the condylar guidance angle was determined by the panoramic radiographs.

Group II A were condylar guidance angle was determined by a conventional technique.

Group II B were the condylar guidance angle was determined by the panoramic radiographs.

Modification of Hanau articulator to measure the horizontal condylar guidance angulations

The Hanau wide Vue-II articulator has a condylar track of numerical scale with increments of 5°. In order to obtain the readings with accuracy up to 1, a protractor modified to have angulations from 0° to 60° was fixed to the condylar shaft (Figures 1 and 2). The center of the protractor was made to coincide with the center of the condylar shaft. Two pointers were attached on to the condylar track. One pointer was attached at the 0° mark on the outer rim of the condylar track. The 0° of the protractor was made to coincide with the 0° pointer while measuring the angle. The second pointer was attached to the groove in the inner rim of the condylar track which indicates the condylar guidance angle. If the pointer was at 0.5 or more decimals on the protractor, then the higher value was considered as the reading, and if the pointer was at <0.5 decimals then the lower value was considered as the reading.

Interocclusal record method for Group I subjects

Maxillary and mandibular dentulous impressions made, and casts were poured. Face bow transfer was done using



Figure 1: Modification of Hanau articulator using template protractor.

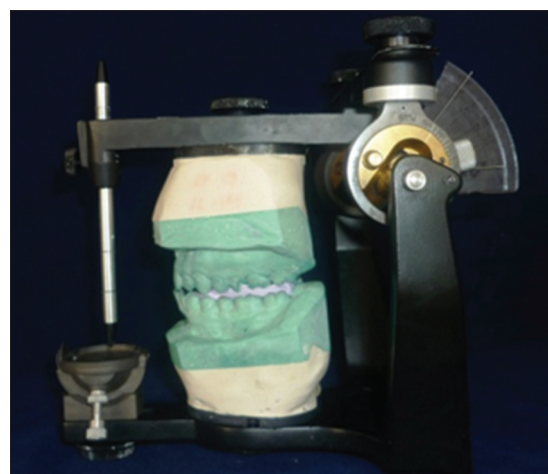

Figure 2: Articulator programmed according to the protrusive interocclusal record.

Hanau spring bow and the maxillary cast was mounted on the articulator. A bite registration was done at the centric and protrusive positions using bite registration paste (Jet bite). The mandibular cast was mounted on the articulator using the centric record. Programming of the articulator was done using protrusive record. The 0° of the protractor was made to coincide with the 0° pointer. The horizontal condylar angle was then read from the protractor. The above mentioned procedure was carried out in all 20 dentulous subjects to obtain the horizontal condylar inclination by interocclusal method respectively.

Interocclusal record method for Group II subjects

Preliminary impressions were made, and primary casts were obtained. Special trays were fabricated. Border molding was done for both the arches and final impressions were made. Impressions were poured, and master casts obtained. Temporary denture bases and occlusal rims were fabricated on the master casts. Customization of the occlusal rims was done for the patient. Tentative jaw relations were recorded. Face bow transfer and gothic arch tracing were done. A bite registration was done at the centric and protrusive positions using bite registration paste (Jet bite). The centric relation was verified using the centric record and programming of the articulator was done using protrusive record. The 0° of the protractor was made to coincide with the 0° pointer. The horizontal condylar angle was read from the articulator. The above-mentioned procedure was carried out in all 20 edentulous subjects to obtain the horizontal condylar inclination by interocclusal method respectively. The readings were tabulated and subjected to statistical analysis.

Radiographic method for Group I and Group II subjects

All the OPG were made in an open mouth position to prevent the superimposition of the image of the condyle over the glenoid fossa in the radiograph. Exposure parameters were set to the standard of 78 kV, 8 mA and exposure time of 10 s on the Panoramic machine (DENTSPLY GENDEXORTHORALIX 9200). Lead apron was used for the subject during exposure to minimize the stray radiation.

Analysis of the obtained radiographs

The panoramic radiographs obtained were traced on acetate sheets. The Frankfort's plane was used as the reference plane for this study. The following salient points were identified and traced on the OPG (Figures 3 and 4). Frankfort's plane was drawn from the Porion (plotted to coincide with the superior border of the radiolucent image of the external auditory meatus) to orbitale (the lower most point on the lower orbital rim). Outline of the glenoid fossa and articular eminence were marked. Point A depicting the deepest point in the glenoid fossa and point B the depicting the highest point on the articular eminence were marked. A line was drawn joining the points A and B. The angle formed by the line joining the points A and B to the line representing the Frankfort horizontal

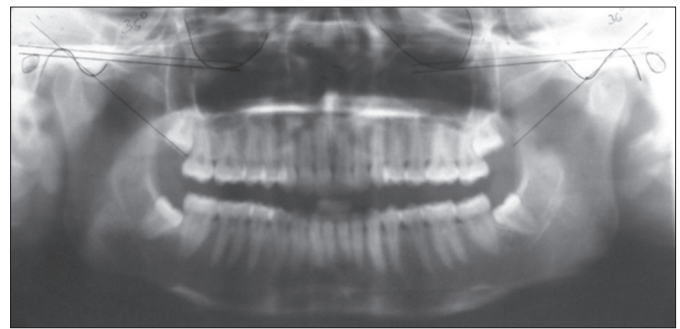

Figure 3: Tracing of condylar guidance angle on panoramic radiograph in dentate patients.

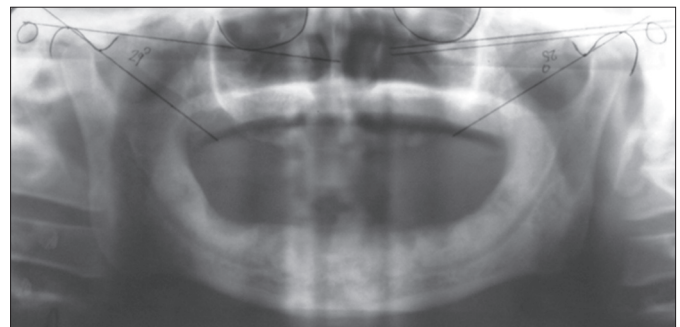


Figure 4: Tracing of condylar guidance angle on panoramic radiograph in edentulous patients.

plane was measured and read as the horizontal condylar guidance angle value obtained by panoramic radiographs [Figures 3 and 4]). The above mentioned procedure was carried out in all the subjects. The readings were tabulated and subjected to statistical analysis

Results

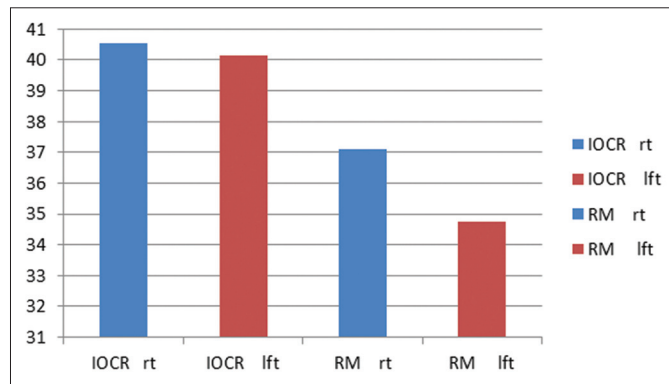
The difference between interocclusal record and radiographic method in the dentate group showed the significant differences ($P < 0.001$) indicating the influence of anterior teeth on resultant condylar guidance. Hence, it could be preferable to use interocclusal method rather than radiographic method. The method to record the bite in protrusion is simpler in dentate individual compared to an arduous process as in edentulous condition (Graph 1).

In edentulous situation before insertion of denture the over jet and overbite do not play any role in determining the amount of disclusion hence the resultant condylar guidance is purely due to the downward and forward movement of the condyle. The condylar angles obtained by both the interocclusal and radiographic methods were relatively close with a mean ranging between 2° and 3° (Graph 2).

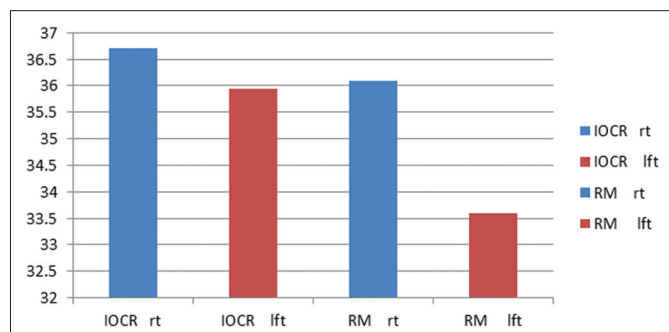
The average angles obtained by radiographic and interocclusal record methods in the present study differed with those obtained by de Freitas in 1970, on a comparison of the radiographic and prosthetic measurement of the sagittal condylar angle. The average values obtained by radiographic

method were 29.08° and 27.74° on the right and left side respectively and 30.12° and 26.60° on the right and left sides respectively by Gysi's technique (Graph 3).

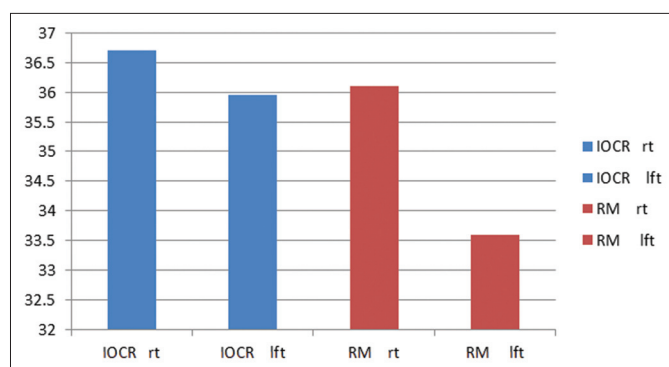
Panoramic radiographs are not only the commonest diagnostic tools in dentistry but also yield replicable results, have a favorable cost-benefit relationship and expose patients to relatively low doses of radiation. Quantitative measurements on panoramic



Graph 1: Comparison of mean values of horizontal condylar guidance angles of the right and left sides obtained by the interocclusal record and radiographic method in the dentate group.



Graph 2: Comparison of mean values of horizontal condylar guidance angles of the right and left sides obtained by the interocclusal record and radiographic method in the edentulous group.



Graph 3: Comparison of mean values of horizontal condylar guidance angles of the right and left sides obtained by the interocclusal record and radiographic method.

radiography are difficult because of magnification differences, and image distortions. However, the reproducibility of vertical and angular measurements is relatively acceptable, if the patient's head is correctly positioned in the equipment. In the present study, for each panoramic radiograph the head was positioned according to the manufacturer's directions. Initially, the condyle appeared to be interfering for valuation hence in our study the open mouth technique was adapted to overcome the condyle superimposing over the glenoid fossa.

On analyzing the data for differences between the radiographic and interocclusal method, it was observed that horizontal condylar guidance angles obtained by radiographic method were lesser than those obtained by the interocclusal method. This difference could be attributed to the influence of overbite while recording the disclusion on the protrusive movement of the mandible. These results were supported by the results obtained by Nandhini in 2005.⁷ On comparing the mean values of right and left sides obtained by the two methods showed a difference of 2.75° and 4.17° respectively between their arithmetic averages.

On analyzing the data obtained from 40 subjects, a significant correlation exists between the horizontal condylar guidance angles determined by the interocclusal method, and radiographic method. OPG could be used as an alternative to clinical methods to overcome the disadvantages associated with conventional techniques. Further studies are required to evaluate the accuracy of radiographs for determining the condylar guidance angles with advanced radiographic techniques.

Discussion

Mandibular movements occur as a complex series of interrelated three-dimensional rotation and translation activities. The two controlling factors that determine these mandibular movements are the condylar path in the TMJ as the posterior controlling factors and the anterior teeth as the anterior controlling factors. The condylar path is peculiar to each individual patient.² The condylar settings should be adjusted using protrusive and lateral interocclusal records.^{8,9} Practical consequences of setting the articulator's condylar guidance higher than the subject's relative angle could possibly result in restorations with protrusive and lateral interferences. Hence, it is very important to set the condylar guidance angle close to actual is important to avoid the resultant interferences.

In clinical practice, the methods most often used to determine the inclination of the sagittal path of the condyles are:

1. The method based on the disocclusion upon protrusion (Christensen phenomenon), which employs intraoral wax records and calculating the angle while programming on the articulator
2. A graphic method in which the condylar path is recorded on a card by means of a face bow. The angle of the path is

obtained by measuring the angle formed by the tangent drawn to the functional portion of the tracing. This method makes it possible to obtain a complete tracing of the condylar path rather than merely determining a point along the condylar path as represented by the interocclusal method.¹⁰

Recording of the condylar guidance angle in edentulous condition involves a complex procedure. The errors may creep in at any stage. Some of the difficulties are the biologic environment are the bases surrounded by the highly versatile tissues like the tongue and the cheek. Movement of these structures may destabilize the bases while recording. Most of the semi-adjustable articulators do not accept lateral records with fidelity. Accurate reading of the condylar guidance is not feasible because these instruments have a numerical scale with increments of 5°. For precise readings of the condylar angle, this scale has to be customized with increments of 1°. Variation in sagittal condylar angle determination by protrusive interocclusal record can also occur due to patient's difficulty to close precisely in protrusion, the degree of protrusion, deformation or compression of the interocclusal record, the quality of the record, due to cast tipping, which is caused by poor adaptation of the casts to the records, force applied by the operator on the record between the maxillary and mandibular member, the position at which the pressure is applied and the sensitivity of the adjustment mechanism.¹¹

The introduction of optoelectronic devices has resolved some of these problems associated with the clinical methods determining of the condylar guidance. However, the clinical usage of these devices requires good neuromuscular control, skill of the operator, time consuming, and the equipment expense is not economical. The use of additional aids, such as dynamic registration or imaging, may resolve these potential problems.

A very early attempt was made to analyze the condylar path through radiographic examination by Boos in 1951. Radiographically, the inclination of the temporal tubercle and the relative position of the condyle can be determined.¹² OPGs are one of the commonly used diagnostic tools in dentistry. Anthropometric studies have shown the use of panoramic radiographs to measure the condylar guidance.¹³

In the present study the mean values of horizontal condylar guidance angle obtained by radiographic method of right and left sides were 36.6° and 34.17° respectively and values of horizontal condylar guidance angle ranged from 24° to 48° with maximum between 30° and 35°. The mean values of horizontal condylar guidance angle obtained by the interocclusal method of right and left sides were 38.62° and 38.05° respectively. The values of horizontal condylar guidance angle ranged from 28° to 50° with a maximum between 35° and 40° (Tables 1 and 2).

Subject	Dentate group			
	Right (degrees)		Left (degrees)	
	IRM	RM	IRM	RM
1	40	34	45	36
2	36	30	42	39
3	37	43	40	36
4	50	46	42	35
5	37	41	38	38
6	51	40	41	32
7	32	33	34	29
8	36	30	41	34
9	46	37	44	36
10	34	28	34	28
11	34	35	42	36
12	33	40	37	41
13	45	36	47	43
14	54	47	44	36
15	45	45	39	31
16	40	39	44	39
17	36	29	30	26
18	40	34	36	29
19	49	43	41	33
20	36	32	42	38

IRM: Interocclusal record method, RM: Radiographic method

Subject	Edentulous group			
	Right (degrees)		Left (degrees)	
	IRM	RM	IRM	RM
1	44	40	44	37
2	30	24	37	28
3	39	45	38	44
4	38	34	32	29
5	28	34	29	33
6	38	32	41	36
7	29	36	32	37
8	38	43	34	34
9	32	40	33	36
10	39	37	41	33
11	41	36	36	30
12	41	34	38	32
13	33	37	32	36
14	42	48	43	44
15	33	31	32	30
16	34	36	31	36
17	36	31	39	31
18	43	37	38	32
19	34	29	33	25
20	42	38	36	29

IRM: Interocclusal record method, RM: Radiographic method

The condylar guidance in dentulous subjects is influenced by the over jet and over a bite of the individual. Greater the steepness of the overbite greater the vertical component of the protrusive glide and greater will be the disclusion. Therefore, steeper overbite results in the higher amount of disclusion and in turn results in higher condylar guidance angle.

Various methods of recording condylar pathways are available, ranging from simple interocclusal method to recently available advanced methods such as pantronic, computerized jaw tracking devices which records precise condylar pathways. The choice of technique depends on the specific clinical needs of occlusal rehabilitation rather than an overriding concern for precise condylar pathways. Hence the simplest and the most convenient method which would suit the particular clinical situation should be chosen to serve the purpose. Further studies by comparing panoramic radiograph to jaw tracking devices would substantiate the results of this study.

References

1. Academy of Prosthodontics. The Glossary of Prosthodontic Terms, 8th ed. St. Louis, MO: Mosby; 2005.
2. Okeson JP. Management of Temporomandibular Disorders and Occlusion, 3rd ed. St. Louis: Mosby Year Book; 1993.
3. dos Santos J Jr, Nelson S, Nowlin T. Comparison of condylar guidance setting obtained from a wax record versus an extraoral tracing: A pilot study. *J Prosthet Dent* 2003;89(1):54-9.
4. Zamacona JM, Otaduy E, Aranda E. Study of the sagittal condylar path in edentulous patients. *J Prosthet Dent* 1992;68(2):314-7.
5. Gysi A, Clapp GW. Practical application of research result in denture construction. *J Am Dent Assoc* 1929;16:92-8.
6. Gonzalez J, Kingery R. Evaluation of plans of references for orienting maxillary casts on articulators. *J Am Dent Assoc* 1959;59:725-32.
7. Nandini VV, Nair C, Sudhakar MC. Comparative evaluation of height tracer, Chandra tracer, intraoral tracer funtiograph & checkbite: A clinical study. *J Indian Prosthodont Soc* 2005;5:26-32.
8. Winkler S. Essentials of Complete Denture Prosthodontics, 2nd ed. USA: Ishiyaku Euro America Inc.; 2000.
9. Morneburg T, Pröschel PA. Differences between traces of adjacent condylar points and their impact on clinical evaluation of condyle motion. *Int J Prosthodont* 1998;11(4):317-24.
10. de Freitas A. A comparison of radiographic & prosthetic measurement of the sagittal path movement of the mandibular condyle. *Oral Surg Oral Med Oral Pathol* 1970;30(5):631-8.
11. Zarb GA, Bolender CL. Boucher's Prosthodontic Treatment for Edentulous Patients, 10th ed. New Delhi: B.I Publishers; 1998.
12. Brandrup-Wogenson T. The face bow: Its significance and application. *J Prosthet Dent* 1953;3(5):618-30.
13. Gills RR. Articulator development and importance of observing the condyle paths in full denture prosthesis. *J Am Dent Assoc* 1926;13:3-25.