

Multidisciplinary Approach in Management of Fractured Central Incisor through Composite Plug Stabilization - A Case Report

Sushil Kumar C¹, Amit Rao², Sheila K³, Hanumanth Reddy G⁴

¹Reader, Department of Conservative and Endodontics, Dr.H.S.R.S.M Dental College Hingoli, Maharashtra, India; ²Professor, Department of Oral and Maxillofacial Surgery, Dr.H.S.R.S.M Dental College Hingoli, Maharashtra, India; ³Senior lecturer, Department of Pediatric and Preventive dentistry, Dr.H.S.R.S.M Dental College Hingoli, Maharashtra, India; ⁴MDS, Professor, Department of Orthodontics, Chhattisgarh Dental College & Research Institute, Rajnandgaon, Chhattisgarh, India.

ABSTRACT

Crown fracture is the most frequent type of traumatic injury in permanent dentition. Traumatized anterior teeth requires quick functional and esthetic repair. Traditionally such injuries have been restored with conventional post-core and crown techniques after endodontic treatment. This article presents an innovative technique of managing a complicate crown fracture of anterior tooth where plain orthodontic band was used for stabilization and post endodontic restoration was done with adhesively luted fiber reinforced composite post through fragment and composite plug stabilization.

Key words: Traumatic injuries, Crown fracture, Composite plug.

How to cite this article: Sushil K C, Rao A, Sheila K, Hanumanth R G. Multidisciplinary Approach in Management of Fractured Central Incisor through Composite Plug Stabilization - A Case Report. *J Int Oral Health* 2013; 5(1):79-82.

Source of Support: Nil

Received: 11th November 2012

Conflict of Interest: None Declared

Reviewed: 12th December 2012

Accepted: 10th January 2013

Address for Correspondence: Dr. Sushil Kumar C, Access Dental Hospital, # 5, & 6 Satya complex, Golnaka Alwal, Secunderabad-10. Email: 16.sushil@gmail.com. Contact no.: 9704171797

Introduction:

Traumatic injuries to the teeth and the supporting structures are one of the few areas in dentistry that should be considered as an emergency. Crown fracture is the most frequent injury in permanent dentition. Apart from loss of hard tissue, this injury represents hazard to pulp. Traumatized anterior teeth requires quick functional and esthetic repair. Traditionally such injuries have been restored with conventional post-core and crown techniques after endodontic treatment. Several factors influences the management of coronal tooth fractures including extent of fracture, pattern of fracture and the restorability of the tooth, presence or absence of the fractured tooth fragment, occlusion and esthetics¹.

Complicated crown fracture in a mature anterior tooth should be immediately treated with method of isolation and restoration becomes difficult. Restoration of esthetics is one of the main concerns in such teeth². This article presents an innovative technique of managing a complicate crown fracture of anterior tooth where plain orthodontic band was used for stabilization and post endodontic restoration was done with adhesively luted fiber reinforced composite post .

Case Report:

A 17 years old female patient walked into department of Conservative dentistry and Endodontics Dr.H.S.R.S.M Dental College at Hingoli, Maharashtra, sustaining a complicated crown fracture to her left upper central incisor. The patient's history for allergy or systemic

problems was non-contributory. Externally mild swelling of the lip was observed. Intraoral clinical examination revealed laceration in the alveolar sulcus in relation to upper incisors. There was no evidence of alveolar fracture. Clinically the upper left central incisor presented with fracture lines running across the crown where the conventional technique of placement of rubber dam clamp and

endodontically following conventional methods. The major concern in this case was giving a proper definitive restoration. After a week of root canal treatment post space was prepared by removing gutta-percha from the root canal space using a no.2 Pezzo drill, leaving the apical third intact. Later a fiber reinforced composite (FRC) post (size 2) was selected. The post space was

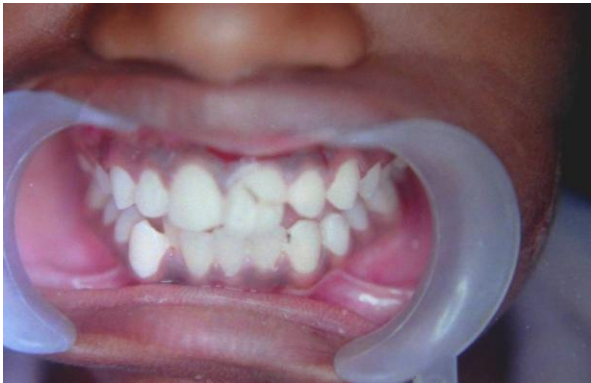

Fig. 1: Pre-operative Photograph of the Fractured 21

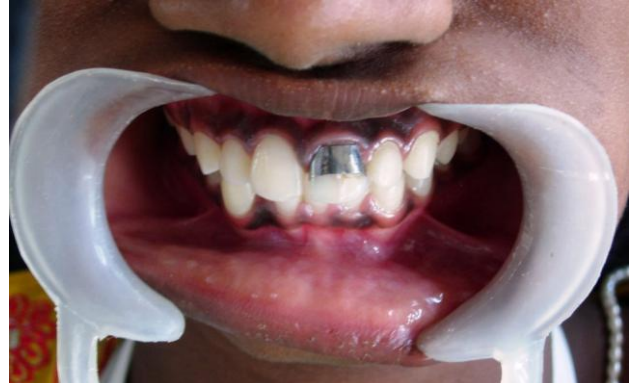

Fig. 2: Stabilization Done with Orthodontic Band

achieving access was not possible. Stabilization and approximation of the fragments was achieved by using pre-formed orthodontic band, which was cemented to the tooth by zinc phosphate cement.

Root canal therapy was performed after proper stabilization with the orthodontic band. Stabilization with the band helped in achieving better access and standard isolation with the help of rubber dam. The tooth was treated

etched for 15secs using 35% phosphoric acid, washed thoroughly and air-dried. Then the post space was painted with bonding agent and light cured for 20secs. The post space was filled with dual curing composite resin cement with the FRC post in place and light cured at an angle of 45° for 40secs at three levels. In this case, bonding of composite resin luting cement to the FRC post is both chemical and mechanical bonding because of

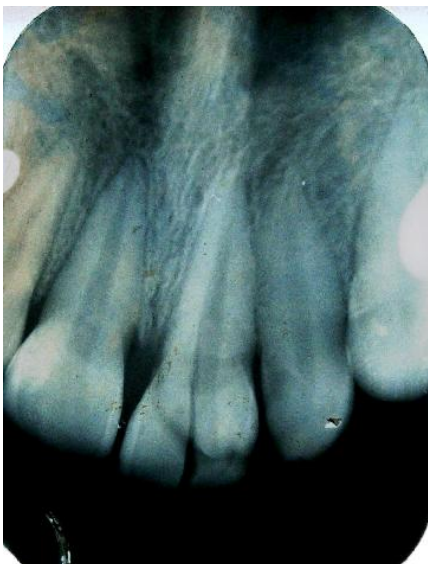

Fig. 3: Pre-operative Radiograph

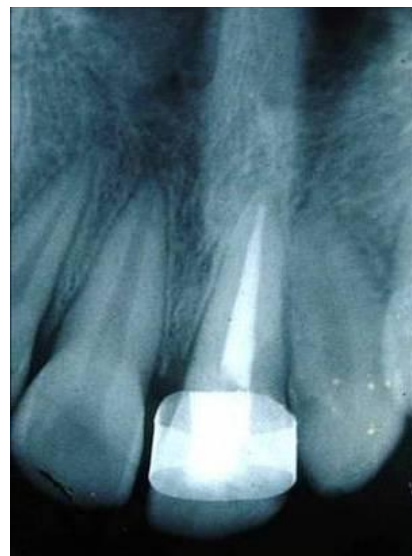

Fig. 4: Post-operative Radiograph Fractured

the isoelastic properties of the resin cement, post and dentin.

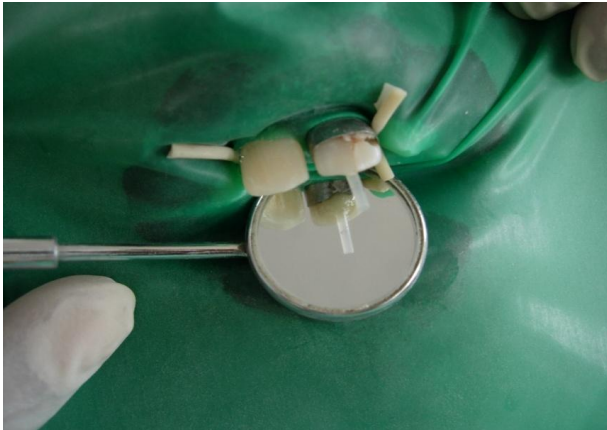

Fig. 5: Placement of FRC Post

In this case, the composite core build-up was replaced by the fragment strengthening of the fractured crown to prevent the natural tooth structure and provide better esthetics. Fragment strengthening of the fractured crown was performed by preparing 3mm of deep grooves of 0.8mm width along the fracture lines leaving the incisal edges. Later composite cement was used along the grooves and light cured. From the post space to the fragment stabilisation resin cement

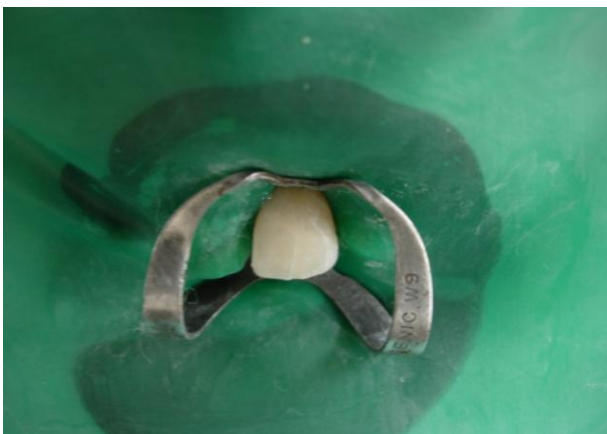


Fig. 7: After Fragment Strengthening

and composite material was used for establishing a plug for better integration and bond strength. This technique of composite plug stabilization exhibits better bond strength between the luting materials, root dentin and FRC posts⁵. After a

week's follow-up the tooth was restored with a provisional crown.

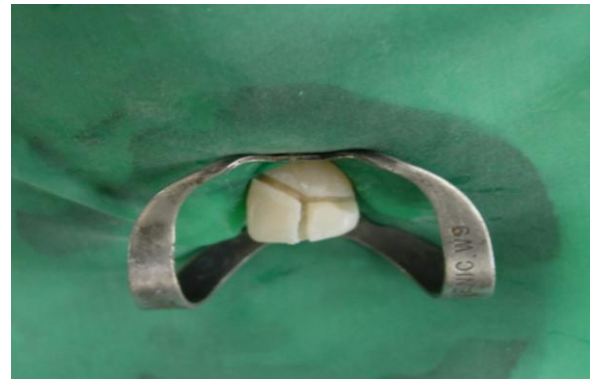

Fig. 6: Grooves prepared along Fracture Lines.

Discussion:

The aim of endodontic and restorative treatment is to restore the function, form and esthetics. Esthetics has an impact on psychology of an adolescent patient when it comes to anterior teeth. Traditionally cast posts have been used for restoration of endodontically treated teeth with complicated crown fracture. Recent advancements in adhesive dentistry lead to the usage of fiber-reinforced resin-based composite posts with resin

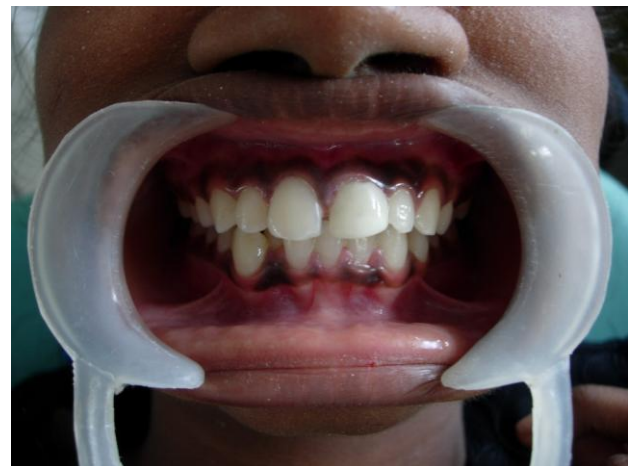

Fig. 8: Provisional Crown.

composite build-ups especially with teeth in the esthetic zone are considered such as maxillary anterior teeth⁶.

Usage of FRC post along with resin cement helps in distribution of stresses along the tooth structure

uniformly thus decreasing the chances of post endodontic failure. Because of the isoelastic properties and similar modulus of elasticity of the FRC post, resin cement and dentin increases the retention and provides monoblock effect⁵.

In this case stabilization of the fractured fragments was achieved by orthodontic band which helped in retention of natural tooth structure and establishment of esthetics. This technique employed was an excellent means of stabilization of the fractured teeth and prevented its demise during the root canal treatment⁷. Fragment strengthening of the fractured crown was possible in this case as there was absolutely no loss of the crown structure apart from the fracture lines running across the tooth. As the original contour was intact, the natural tooth structure acted as biological contour for better resistance.

Conclusion:

In a traumatic injury to the tooth, the success of the endodontic treatment depends on the remaining tooth structure. Though a FRC post was used for support maximum effort was put to save the natural tooth structure for better esthetics and function. The current case report illustrates a viable and conservative technique by which the fractured tooth can be stabilized without any fragment loss through which both function and esthetics were established.

References:

1. Macdeo GV, Diaz PI, De O Fernandes CA. Reattachment of Anterior Teeth Fragments: A Conservative Approach. *J Esthet Restor Dent*; 2008;20:5-20.
2. Andreason FM, Andreason JO. Crown root fractures: Textbook and colour atlas of traumatic injuries to the teeth, 3rd edition. Copenhagen, Munksgaard, 1994;219-56.
3. Ingle J, Bakland LF. Endodontic considerations in dental trauma. *Endodontics*, 5th edition. Elsevier.2002;795.
4. ZJohn SR. Advanced endodontics. Clinical Retreatment and Surgery, 2nd edition. New York, 2006;17.
5. Tay FR, Pashley DH. Monoblocks in root canals: A hypothetical or a Tangible Goal. *J.Endod* 2007;33:391-8.
6. Reis A, Kraul A. Reattachment of fractured teeth, A review of literature regarding techniques and materials. *Oper Dent*. 2004;29(2):226-33.
7. Reis A, Kraul A. Francei C. Reattachment of anterior fractured teeth. Fracture strength using different materials. *Oper Dent*. 2008;27:621-7.