

## A Retrospective Radiographic Survey of Pathology Associated with Impacted Third Molars among Patients Seen in Oral & Maxillofacial Surgery Clinic of College of Dentistry, Riyadh

Naveed Ahmad Khawaja<sup>1,2</sup>, Hesham Khalil<sup>3</sup>, Kauser Parveen<sup>4</sup>, Abdulmajeed Al-Mutiri<sup>5</sup>, Saif Al-Mutiri<sup>5</sup>, Abdullah Al-Saawi<sup>5</sup>

### Contributors:

<sup>1</sup>Faculty, Department of Oral & Maxillofacial Surgery, College of Dentistry, King Saud University, Riyadh, Kingdom of Saudi Arabia; <sup>2</sup>Assistant Professor, Department of Maxillofacial Surgery and Pathology, Nishtar Institute of Dentistry, Multan, Pakistan; <sup>3</sup>Associate Professor, Department of Oral & Maxillofacial Surgery, College of Dentistry, King Saud University, Riyadh, Kingdom of Saudi Arabia; <sup>4</sup>Lecturer, Department of Dental Health, College of Applied Medical Sciences, King Saud University, Riyadh, Kingdom of Saudi Arabia; <sup>5</sup>Interns, College of Dentistry, King Saud University, Riyadh, Kingdom of Saudi Arabia.

### Correspondence:

Dr. Khawaja NA. Faculty, College of Dentistry, King Saud University, P.O. Box 60169, Riyadh 11545, Kingdom of Saudi Arabia. Office: +966 (0)1 467 7438, Phone: 00966 (0) 502887783, Email: nakhawaja@hotmail.com

### How to cite the article:

Khawaja NA, Khalil H, Parveen K, Al-Mutiri A, Al-Mutiri S, Al-Saawi A. A retrospective radiographic survey of pathology associated with impacted third molars among patients seen in Oral & Maxillofacial Surgery Clinic of College of Dentistry, Riyadh. *J Int Oral Health* 2015;7(4):13-17.

### Abstract:

**Background:** The purpose of this study is to determine the type and frequency of pathological conditions around third molar teeth among randomly selected patient's records in Oral and Maxillofacial Surgery, College of Dentistry, King Saud University, Riyadh.

**Materials and Methods:** Totally, 281 patient panoramic radiographs were selected with detectable pathology among 570 files of patients seen in oral and maxillofacial surgery clinics 2 years retrospectively. Almost 17-55 years age (mean age 25.43) was selected. The following radiographs were analyzed for all pathology associated impacted teeth; dental caries, bone resorption, periodontitis, and apical pathology.

**Results:** The study found caries, external bone resorption and periodontitis are highly frequent to mesioangular and horizontal in mandibular impacted third molar compared to maxillary impacted third molar. Overall result evaluated that tooth #28 related periodontitis is significant ( $P = 0.021$ ), and tooth #38 related bone resorption, tooth #48 related root caries, bone resorption and apical pathology are highly significant ( $P = 0.000$ ) comparing to others. This study also concluded the high frequency of root caries, bone resorption and apical pathology reported in relation to mandibular impacted third teeth. Significant results were also achieved with periodontitis in relation to mesioangular and vertical angulation of left impacted maxillary third molars.

**Conclusion:** Prophylactic removal of impacted third molars is recommended in many studies to avoid future risk of associated pathology. Retained asymptomatic impacted third molars imply

pathology that could be difficult in later ages as less morbidity in younger ages.

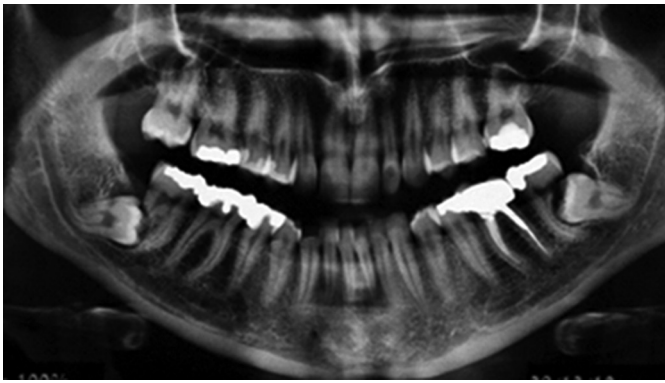
**Key Words:** Impacted teeth, panoramic radiograph, pathology

### Introduction

An impacted tooth can be defined as one which is unable to erupt into position within its time of eruption because of malposition or lack of space. Third molars normally erupt between 18 and 25 years.<sup>1</sup> Approximately 40% of third molar teeth become impacted due to lack of space. If teeth impacted,<sup>2</sup> then the most of these retained asymptomatic impacted molars establish an abnormal/poor relation with the adjacent tooth and more potential for risk of different complications.

Many studies<sup>1-5</sup> were undertaken regarding the opinions about prophylactic removal with or without symptomatic due to expected complications. Local complications (food impaction, soft tissue inflammation and pain) can be happened with retained impacted teeth. Therefore, a potential pathology associated to third molars was suspected like dental caries, root caries, bone resorption, apical pathosis, soft tissue infection, periodontal problems, bone resorption and cyst/tumor (Figure 1). However, prophylactic removal of impacted third molars, free from any pathology, is still a common practice and also debatable.<sup>6</sup> Another study explained the decision to extract prophylactic depends on the balance between the likelihood of potential of impacted tooth causing pathology in future and risk of surgery.<sup>7</sup> Regarding early removal of third molars, The American Association of Oral and Maxillofacial Surgeons recommends extraction of all four third molars in young adulthood stage, preferably in adolescence, before the roots are fully formed to minimize complications such as post extraction pain and infection but there are no randomized controlled studies to compare the long-term outcome of early removal with retention of pathology-free third molars.<sup>8</sup>

Although many literatures has been mentioned about the potential for development of pathologic changes around impacted third molars in people from different countries. One study<sup>5</sup> found no pathologic changes around asymptomatic impacted third molar but another study<sup>3</sup> reported third molar-related pathology that is only 1-4.5% of impacted third molar cause caries in the adjacent tooth crown and <1% second molar root resorption. Very rare periapical cysts and no significant risk of development of third molar germ cell tumors were



**Figure 1:** Orthopantomography showing pathology associated impacted third molars.

reported. This study also dictated 10% chronic inflammatory complications. Another prospective cohort study<sup>4</sup> measured prevalence of disease associated impacted third molar. The study estimated 8% periodontitis, 5% caries in the second molar and 1% root resorption of the second molar. Odds ratio was highest for distoangular (DA).<sup>5,9</sup>

One recent study<sup>10</sup> concluded the retention of third molars is associated with increased risk of second molar pathology; caries related to second molar and periodontitis related to third molar in middle-aged and older adult men. Also found that the lowest prevalence and incidence of second molar pathology occurred when the adjacent third molar was absent.

The purpose of this present study is to determine the type and frequency of radiographic detectable pathological conditions in association to different types of impacted third molar among the patients seen in King Saud University, Maxillofacial Surgery of College of Dentistry.

### Materials and Methods

In this study, we selected radiographs from the patients file of age 17-55 years seen in Oral and Maxillofacial Surgery retrospectively 2 year to survey pathology associated with impacted third molar in different angulation in relation to long axis of second molar and according to the system developed by Pell and Gregory<sup>2,5</sup> mesioangular (MA), DA, horizontal (H) and vertical (V).

Information and sample are collected by three examiners according to designed performa from the files of the patients seen in Oral Maxillofacial Surgery of College of Dentistry. All of the cases were studied on radiographs; panoramic (orthopantomography [OPG]), periapical and bitewings views to see radiographic detectable pathology in related to third molar impaction. Inclusive criteria of selected patients were medical fit.

Caries in second molars, bone resorption in between second and third molar, apical pathology and periodontitis in the

second molar were selected pathology for this study. Bone resorption alone or in association with attachment loss (periodontitis) was seen in radiographs. Caries was mostly studies in bitewing view to confirm.

Data analysis was done using SPSS 20 version resulting in Pearson Chi-Square.

### Results

Totally, 281 radiographs were selected with detectable pathology among 570 files of patients. 17-55 years age (mean age 25.43) was selected, 159 (56.58%) were males, and 122 (34.42%) were females. In this study, detectable pathology associated was seen in different angulation of impacted third molar in relation to the second molar in different age group.

In this study, we divided the patient in three age groups, first age group (17-25) is most common age of eruption accounts for 141 (50.2%), second age group (26-35), which is important to show more complication when impacted third molar is retained in this age 113 (40.2%) and third last age group (36-55 or above), which is less in number and common age of late complications in retained impacted third molar explain the frequency of impaction in three age group.

This study explains frequency of impaction in different age groups. Incidence of maxillary impacted teeth is most common "vertical" in first age and second age group 18 (69%, 46.7% respectively), 28 (73.9%, 63.2% respectively) comparing other (Table 1). Data analysis of this study also shows that there is no horizontal position in maxillary third molar, both right and left side. On other hand, most common impacted in mandible is "mesioangular (MA)" in first and second age group 38 (48.1%, 27.7% respectively), 48 (57.3%, 23.8% respectively). This also concluded that second common mandibular impacted is horizontal 38 (29.6%, 42.2% respectively), and 48 (23.3%, 46.3% respectively). Results are mostly not significant in all impaction except tooth #48 ( $P = 0.000$ ) which is highly significant (Table 1).

Incidence of caries and periodontitis related to mesioangular position of the tooth #18 is high (26.9%) and caries incidence is higher in vertical angulation of the tooth #28 (25%). Result of periodontitis pathology related to tooth #28 is significant ( $P = 0.021$ ) comparing to other pathology related to teeth #18 and 28 (Table 2).

Caries, bone resorption and periodontitis in relation to MA and horizontal positions of tooth #38 and #48 are higher. Fewer incidences were seen in association to the vertical position of the tooth #38 and 48 comparing to this. Bone resorption is highly significant in association to tooth #38 ( $P = 0.000$ ). Furthermore, root caries, bone resorption, and apical pathology

Table 1: Frequency of impacted third molars among age groups.

Tooth	Angulation	Age groups			Results P value
		17-25 n=141 (50.2%)	26-35 n=113 (40.2%)	36-55 or above n=27 (9.6%)	
#18	MA	10 (23.8)	13 (43.3)	3 (33.3)	0.431
	DA	3 (7.1)	2 (6.7)	X	
	H	X	1 (3.3)	X	
	V	29 (69.0)	14 (46.7)	6 (66.7)	
#28	MA	8 (17.4)	3 (7.9)	1 (33.3)	0.212
	DA	4 (8.7)	10 (26.3)	X	
	H	X	1 (2.6)	X	
	V	34 (73.9)	24 (63.2)	2 (66.7)	
#38	MA	52 (48.1)	23 (27.7)	3 (93.8)	0.058
	DA	7 (6.5)	3 (30.0)	X	
	H	32 (29.6)	35 (42.2)	2 (25.0)	
	V	17 (15.7)	22 (26.5)	3 (37.5)	
#48	MA	59 (57.3)	19 (23.8)	3 (18.8)	0.000
	DA	5 (4.9)	4 (5.0)	X	
	H	24 (23.3)	37 (46.3)	5 (31.3)	
	V	15 (14.6)	20 (25.0)	8 (50.0)	

MA: Mesioangle, DA: Distoangle, H: Horizontal, V: Vertical

Table 2: Pathology associated to angulation in all impacted third molars.

Tooth	Angulations	Pathology n (%)				
		Caries M2 (%)	Root caries M2	Bone resorption	Apical pathosis	Periodontitis
#18	MA	7 (26.9)	3 (11.5)	X	X	7 (26.9)
	DA	1 (20.0)	X	X	X	X
	H	X	X	X	X	X
	V	8 (16.3)	2 (4.1)	3 (6.1)	1 (2.0)	4 (8.2)
	Result	0.693	0.561	0.565	0.882	0.106
#28	MA	5 (41.7)	1 (8.3)	X	X	3 (25.0)
	DA	1 (7.1)	X	X	X	X
	H	X	X	X	X	X
	V	15 (25.0)	2 (3.3)	3 (5.0)	X	2 (3.3)
	Result	0.207	0.706	0.706		0.021
#38	MA	36 (46.2)	3 (3.8)	13 (23.1)	9 (11.5)	28 (35.9)
	DA	6 (60)	X	4 (40.0)		3 (30)
	H	31 (44.9)	8 (11.6)	32 (46.4)	8 (11.6)	25 (36.2)
	V	15 (37.7)	1 (2.4)	4 (9.5)	1 (2.4)	20 (46.6)
	Result	0.499	0.109	0.000	0.222	0.542
#48	MA	28 (34.6)	4 (4.9)	21 (25.9)	2 (2.5)	30 (37.0)
	DA	3 (33.3)	X	3 (33.3)	X	3 (33.3)
	H	27 (40.9)	16 (24.2)	24 (63.6)	15 (25.6)	28 (42.4)
	V	20 (46.5)		8 (8.6)		22 (51.2)
	Result	0.592	0.000	0.000	0.000	0.461

MA: Mesioangle, DA: Distoangle, H: Horizontal, V: Vertical

are highly significant in relation to tooth #48 ( $P = 0.000$ ), most probably because of habit using more one side (Table 2).

Overall result evaluate that tooth #28 related periodontitis is significant ( $P = 0.021$ ), tooth #38 related bone resorption, tooth #48 related root caries, bone resorption and apical pathology are highly significant ( $P = 0.000$ ) comparing to others.

### Discussion

Results of this study concluded that the tooth #28 related periodontitis was significant, tooth #38 related bone resorption, tooth #48 related root caries, bone resorption and apical pathology were highly significant comparing to others.

Although there is general agreement by dentists and literatures that the presence of pathology associated with impacted third molar teeth is an indication for their removal, prophylactic removal is still controversial. One recent study opposing this idea<sup>11</sup> and in another study favoring of prophylactic removal.<sup>12</sup> Many studies evaluated to remove impacted third molar as prophylaxis to avoid expected risk of associated pathology and less morbidity.

Panoramic radiographs are routinely employed for surgical planning of impacted third molar to study the relationship of the impacted tooth to surrounding structures. One should be careful to consider that one study explained the distortion in

position of mandibular third molar found  $5.37^\circ$  between OPG and study cast.<sup>9</sup>

Regarding the pattern of impacted third molar in this study, mesioangular are found more frequent in first and second age group but found a high ratio of lower impacted third molars than the upper. Similarly, incidence of vertical angulation of upper impacted third molar is high in first and second age group. This study did not evaluate level/depth or eruption status. However, result of angulation in relation to right impacted third molar is highly significant ( $P = 0.000$ ) (Table 1).

In this study, we did not find horizontal maxillary impacted third molar (Table 2). We found a high incidence of caries, bone resorption and periodontitis mostly in relation to MA, horizontal and vertical angulation of mandibular impacted third molars.

This study did not include third molar itself for caries. One study<sup>13</sup> recorded high ratio of dental caries in third molars (21.5%) in association of impacted third molars among 1398 patients in retrospective radiographs. The study investigated apical radiolucency proved to be chronic apical inflammation in the form of granuloma/cyst or abscess. It is evident in the data of one previous study<sup>14</sup> that estimated 25% of 329 patients with retained asymptomatic third molars have considerable periodontal pathology in the third molar region, about more than 2 mm attachment loss on the distal of a second molar or around the adjacent third molar.

Root resorption alone and in association to attachment loss are considered separately in this study. Periodontitis of adjacent second molar tooth is most common in relation to mesioangular and vertical angulation of upper impacted third molars in this study. It is significant for upper impacted third molar ( $P = 0.021$ ). No significant result of periodontitis was found in relation to lower impacted third molar, but we found highly significant result in bone resorption ( $P = 0.000$ ) in association to lower impacted third molars (Table 2). A similar study<sup>15</sup> evaluated the symptoms/pathology with pattern of impaction of mandibular third molar in 472 patients between 16 and 54 ages. Of the 472 impacted teeth, 270 (57.51%) were associated with pathology that included 57.5% with periodontitis, 13.95% with caries while 0.63% were associated with cysts.

Many studies<sup>16-25</sup> were undertaken regarding pathology associated to impacted third molar impaction which most of them agreed with prophylactic removal of third molars as future risk of diseases.

Our study demonstrated the findings of pathology associated with impacted third molars in general agreement with the others. In this study, caries is more evident in relation to MA angulation in all impacted third molars but not showed

significant results. We found root caries and apical pathology with highly significant ( $P = 0.000$ ) result in association to right mandibular impacted third molar because of the possibility of one-sided eating habit factor (Table 2). One study<sup>24</sup> estimated high incidence of superimposition and root resorption (root caries) of the second molar in association of retained impacted third molar in elderly individuals over 50 years of age.

Different data<sup>26-29</sup> suggest that the absence of symptoms associated with retained third molars does not always show the absence of disease or pathology. The clinical implications of findings suggest that patients with retained their third molars should have regular periodic clinical and radiographic examinations to detect disease before it becomes symptomatic. The potential for the retained third molars is to serve as a chronic source of inflammation.

### Conclusion

Prophylactic removal of impacted third molars is recommended in many studies to avoid future risk of associated pathology. Retained asymptomatic impacted third molars imply pathology that could be difficult in later ages as less morbidity in younger ages. We further can go to consider the pathology associated with level/depth of impacted third molar in different age groups.

### References

1. Rantanen A. The age of eruption of third molar teeth. *Acta Odontol Scand* 1974;44:141-5.
2. Pell GJ, Gregory GT. Impacted mandibular third molars: classification and modified technique for removal. *Dent Dig* 1933;39:330-8.
3. Daley TD. Third molar prophylactic extraction: a review and analysis of the literature. *Gen Dent* 1996;44(4):310-20.
4. Knutsson K, Brehmer B, Lysell L, Rohlin M. Pathoses associated with mandibular third molars subjected to removal. *Oral Surg Oral Med Oral Pathol Oral Radiol Endod* 1996;82(1):10-7.
5. Peterson LJ, Ellis E, Hupp JR, Tucker MR. *Contemporary Oral & Maxillofacial Surgery*, 4<sup>th</sup> ed. St. Louis: CV Mosby; 2003.
6. Song F, Landes DP, Glennly AM, Shedon TA. Prophylactic removal of impacted third molars: An assessment of published reviews. *Oral Surg* 1997;182:339-46.
7. Prophylactic removal of impacted third molars: is it justified? *Br J Orthod* 1999;26:149-51.
8. American Association of Oral and Maxillofacial Surgeons. *Wisdom Teeth*. Available from: [http://www.aaoms.org/wisdom\\_teeth.php](http://www.aaoms.org/wisdom_teeth.php). [Last accessed on 2011 Jan 23].
9. Sant'Ana LF, Giglio FP, Ferreira O Jr, Sant'ana E, Capelozza AL. Clinical evaluation of the effects of radiographic distortion on the position and classification of mandibular third molars. *Dentomaxillofac Radiol* 2005;34(2):96-101.
10. Nunn ME, Fish MD, Garcia RI, Kaye EK, Figueroa R,

- Gohel A, *et al.* Retained asymptomatic third molars and risk for second molar pathology. *J Dent Res* 2013;92(12):1095-9.
11. Hill CM. Removal of asymptomatic third molars: an opposing view. *J Oral Maxillofac Surg* 2006;64:1816-20.
  12. Louis KF. Removal of asymptomatic third molars: A supporting view. *J Oral Maxillofac Surg* 2006;64:1811-5.
  13. Al-Khateeb TH, Bataineh AB. Pathology associated with impacted mandibular third molars in a group of Jordanians. *J Oral Maxillofac Surg* 2006;64(11):1598-602.
  14. Blakey GH, Marciani RD, Haug RH, Phillips C, Offenbacher S, Pabla T, *et al.* Periodontal pathology associated with asymptomatic third molars. *J Oral Maxillofac Surg* 2002;60(11):1227-33.
  15. Obiechina AE, Arotiba JT, Fasola AO. Third molar impaction: evaluation of the symptoms and pattern of impaction of mandibular third molar teeth in Nigerians. *Odontostomatol Trop* 2001;24(93):22-5.
  16. Adeyemo WL. Do pathologies associated with impacted lower third molars justify prophylactic removal? A critical review of the literature. *Oral Surg Oral Med Oral Pathol Oral Radiol Endod* 2006;102(4):448-52.
  17. Güven O, Keskin A, Akal UK. The incidence of cysts and tumors around impacted third molars. *Int J Oral Maxillofac Surg* 2000;29(2):131-5.
  18. Werkmeister R, Fillies T, Joos U, Smolka K. Relationship between lower wisdom tooth position and cyst development, deep abscess formation and mandibular angle fracture. *J Craniomaxillofac Surg* 2005;33(3):164-8.
  19. McArdle LW, Renton TF. Distal cervical caries in the mandibular second molar: an indication for the prophylactic removal of the third molar? *Br J Oral Maxillofac Surg* 2006;44(1):42-5.
  20. Sewerin I, von Wowern N. A radiographic four-year follow-up study of asymptomatic mandibular third molars in young adults. *Int Dent J* 1990;40(1):24-30.
  21. van der Linden W, Cleaton-Jones P, Lownie M. Diseases and lesions associated with third molars. Review of 1001 cases. *Oral Surg Oral Med Oral Pathol Oral Radiol Endod* 1995;79(2):142-5.
  22. Shugars DA, Jacks MT, White RP Jr, Phillips C, Haug RH, Blakey GH. Occlusal caries experience in patients with asymptomatic third molars. *J Oral Maxillofac Surg* 2004;62(8):973-9.
  23. Chu FC, Li TK, Lui VK, Newsome PR, Chow RL, Cheung LK. Prevalence of impacted teeth and associated pathologies – a radiographic study of the Hong Kong Chinese population. *Hong Kong Med J* 2003;9(3):158-63.
  24. Yamaoka M, Furusawa K, Ikeda M, Hasegawa T. Root resorption of mandibular second molar teeth associated with the presence of the third molars. *Aust Dent J* 1999;44(2):112-6.
  25. Nitzan D, Keren T, Marmary Y. Does an impacted tooth cause root resorption of the adjacent one? *Oral Surg Oral Med Oral Pathol* 1981;51(3):221-4.
  26. Marciani RD. Is there pathology associated with asymptomatic third molars? *J Oral Maxillofac Surg* 2012;70(9 Suppl 1):S15-9.
  27. Fisher EL, Garaas R, Blakey GH, Offenbacher S, Shugars DA, Phillips C, *et al.* Changes over time in the prevalence of caries experience or periodontal pathology on third molars in young adults. *J Oral Maxillofac Surg* 2012;70(5):1016-22.
  28. Campbell JH. Pathology associated with the third molar. *Oral Maxillofac Surg Clin North Am* 2013;25(1):1-10, v.
  29. Offenbacher S, Beck JD, Moss KL, Barros S, Mendoza L, White RP Jr. What are the local and systemic implications of third molar retention? *J Oral Maxillofac Surg* 2012;70(9 Suppl 1):S58-65.